

**OFFICE OF THE MEDICAL EXAMINER
Center for Forensic Medicine
Nashville, Tennessee**



REPORT OF INVESTIGATION BY COUNTY MEDICAL EXAMINER

Davidson County Medical Examiner: Feng Li M.D., J.D., Ph.D.

Judicial District Number: 20

District Attorney: Honorable Glenn Funk

State Number: 23-19-2158

Case Number: MEC23-1142

Name of Decedent Audrey Elizabeth Hale		Age 28 Years	Race White	Date of Birth 03/24/1995	Sex Female
Address [REDACTED]					
Date of Death 03/27/2023 10:15 PM		Type of Death Suspected Homicide		Investigating Agency/Complaint #: Metro Nashville Police Dept, Complaint #: 2023-0181711	
Place of Death 33 Burton Hills Drive, Nashville, TN					
Narrative Summary Reportedly, this 28-year-old female sustained multiple gunshot wounds at the hands of another/others during a mass shooting at a Nashville school on 03/27/2023. MNPd officers confirmed obvious death on scene. Investigator Krista Hammonds, accompanied by Dr. Emily Dennison, responded to the location to document the scene with photography and to perform a brief body examination. Investigator Hammonds officially pronounced death at 22:15 hours. Medical examiner jurisdiction was accepted, and the decedent will be transported to the Center for Forensic Medicine by Middle Tennessee Removal Service for examination. Final disposition arrangements are undecided at the time of this report. Investigator Megan Whitesell 03/27/2023 2050 hours					
Jurisdiction Accepted Yes		Autopsy Ordered Yes		Toxicology Ordered Yes	
Physician Responsible for Death Certificate Emily H Dennison, M.D.					
Cremation Approved No		Funeral Home Nashville Funeral and Cremation Service			
Cause of Death Gunshot Wounds					
Contributory Cause of Death					
Manner of Death Homicide					

OFFICE OF THE MEDICAL EXAMINER
Center for Forensic Medicine
850 R.S. Gass Blvd.
Nashville, Tennessee 37216-2640

CASE: MEC23-1142
County: DAVIDSON

AUTOPSY REPORT

NAME OF DECEDENT: HALE, AUDREY ELIZABETH **SEX:** Female **AGE:** 28

DATE AND TIME OF AUTOPSY: March 28, 2023 at 12:02 p.m.

FORENSIC PATHOLOGIST: Emily H. Dennison, M.D.

PATHOLOGIC DIAGNOSES

1. Perforating gunshot wound "A" of the torso and left arm:
 - a. Pathway: Perforation of the right 5th intercostal space and rib, right lung, aorta, 6th thoracic vertebrae, left lung, left 2nd intercostal space, left axilla, and soft tissue of the left arm.
 - b. Associated injuries: Bilateral hemothoraces (right 140 milliliters, left 220 milliliters), rib fractures, vertebral fracture, pulmonary lacerations, and soft tissue hemorrhage.
 - c. Direction: Right to left, back to front, and slightly downward.

 2. Perforating gunshot wound "B" of the head:
 - a. Pathway: Perforation of the scalp and graze of the left parietal bone.
 - b. Associated injuries: Skull fracture and subarachnoid hemorrhage.
 - c. Direction: Slightly back to front, right to left, and upward.

 3. Superficial aggregate/graze wounds "C" of right shoulder:
 - a. Superficial penetration of the soft tissue of the right shoulder.
 - b. Direction: Right to left.

 4. Perforating gunshot wound "D" of the right thigh:
 - a. Pathway: Perforation of the soft tissue, vasculature and femur of the right leg.
 - b. Associated injuries: Right femur fracture and soft tissue hemorrhage.
 - c. Direction: Right to left.

 5. Minor blunt force trauma of the body.
-

CAUSE OF DEATH:	Gunshot Wounds
MANNER OF DEATH:	Homicide
CIRCUMSTANCES OF DEATH:	Decedent was shot by another person(s).

The autopsy was performed at the Center for Forensic Medicine. The purpose of this report is to provide a certified opinion to the County Medical Examiner and District Attorney General. The facts and findings to support these conclusions are filed with the Tennessee Department of Health. The autopsy was performed in the presence of Kevin Jenkins, M.D.

EXTERNAL EXAMINATION

CLOTHING: The body is viewed on scene wearing a white shirt (cut) with handwritten words, drawings and numbers written on it, a black tee shirt (cut) with a firing range logo printed on the left front side of the shirt and other printed writings and a picture on the back, a pink-tan bra (cut) that has handwritten words and a drawing on it, a black tactical-type vest, a black utility belt with holsters attached, red underwear, camouflage pants (cut), two red socks, two black shoes, orange ear plugs, two black and blue partial gloves, and an orange smartwatch. A red hat is viewed near the body. Multiple ammunition magazines (some labeled with stickers and/or drawings) and other weapon items, including what appears to be a red pocket knife with the name "AIDEN" monogrammed on it, are removed from the clothing on scene and handed over to law enforcement. The hands have been handcuffed behind the back with white metal handcuffs; these handcuffs are removed at the scene and are handed over to law enforcement.

RADIOGRAPHY: A postmortem x-ray is reviewed.

The body is that of a well-developed, well-nourished, 5 foot 2 inch, 119-1/2 pound phenotypic female who appears to be the reported age of 28 years. The Body Mass Index is 21.9 kilograms per meter squared. The body is refrigerated, well preserved, and not embalmed; the body is not jaundiced. An orange plastic bracelet around the right ankle has the inscription "508407".

The head is normocephalic. The skin of the head and neck is not plethoric. The scalp has up to 15 centimeter in length, brown wavy hair in a normal distribution. A curvilinear scar is on the right side of the forehead. The face is not congested. The irides are brown. The pupils are round and each is 5 millimeters in diameter. The corneas are clear. The sclerae are white. The conjunctivae have no petechiae. The nasal septum and nasal bones are intact. The ears are unremarkable. The teeth are natural and in good repair. The oral mucosa is not injured.

The neck and chest are symmetrical. The nipples and breasts are symmetrical and have no palpable masses.

The abdomen is soft and flat. The posterior torso has a normal contour.

The joints are not deformed. The arms have no track marks. The wrists have no scars. The fingernails are intact and have no cyanosis or clubbing. The lower extremities have no peripheral edema.

The external genitalia consists of an adult, atraumatic, vulva. The anus is unremarkable.

TATTOOS: None.

EVIDENCE OF MEDICAL INTERVENTION: Black tourniquets encircle the bilateral thighs.

EVIDENCE OF INJURY:

Blunt Force Trauma of the Body:

A 4 x 1 centimeter area of red-orange abrasions extends from the left side of the chin onto the left side of the neck. A 4 x 0.5 centimeter red-orange abrasion is near the base of the left side of the neck. A 1 x 1 centimeter red abrasion is towards the medial aspect of the posterior aspect of the left shoulder.

There are multiple, scattered, 1-3 centimeter in greatest dimension, yellow abrasions that extend down the anterior aspect of the left arm through the left antecubital fossa and onto the anterior aspect of the left forearm. A 3 centimeter laceration is on the posterior aspect of the base of the left fifth finger. A 1 x 1 centimeter purple contusion is on the posterior aspect of the right forearm. A 6 x 5 centimeter purple contusion is on the right palm near the base of the thumb. There are linear, vertically-oriented red-orange abrasions that are 3.5 x 0.1 centimeters and 3 x 0.5 centimeters that extend down the anterior aspect of the right thigh. A 6 x 0.5 centimeter area of red-orange abrasions extends between these two linear abrasions on the right thigh. A 6 x 5 centimeter purple contusion is on the right shin. There is a 6 x 2 centimeter area of red-orange abrasions on the anterolateral aspect of the left thigh. A 4.5 x 1 centimeter red-orange abrasion is towards the anteromedial aspect of the left thigh. A 3.5 x 1 centimeter red abrasion is on the left knee and this is surrounded by a 13 x 8 centimeter purple contusion on the left knee.

A 1 x 0.5 centimeter defect (labeled "4" in the diagrams and photographs) is on the right knee and is 15 inches above the bottom of the right foot. This defect has some dark discoloration around the edges of the wound but this wound does not track as a gunshot wound. There are no projectile fragments recovered from this area. It is unclear if this defect represents a wound from a ricochet portion of a projectile or a portion of glass. There are pinpoint red abrasions surrounding the wound.

Perforating Gunshot Wound "A" of the Torso and Left Arm:

An entrance-type gunshot wound (labeled "6" in the diagrams and photographs) is 10 inches below the top of the head and 3-3/4 inches to the right of the posterior aspect of the midline on the posterior aspect of the right shoulder. The 0.5 x 0.3 centimeter defect has a 0.3 centimeter abrasion from 1-4 o'clock. No soot or stippling is associated with this wound.

The projectile perforated through the posterior aspect of the right fifth intercostal space and rib before perforating through the right upper lung lobe, the aorta and the anterior aspect of the sixth thoracic vertebrae. The projectile then perforated through the hilum of the left lung, the left upper lung lobe and the anterior aspect of the left second intercostal space before perforating

through the soft tissue and vessels of the left axilla. The projectile then perforated through the soft tissue of the left arm and exited the body through an exit-type gunshot wound (labeled "5" in the diagrams and photographs), 4 inches below the top of the left shoulder on the anterolateral aspect of the left arm. The 1.1 x 1 centimeter defect has a 6 x 4 centimeter purple contusion surrounding the wound. No soot or stippling is associated with this wound. No projectile fragments are recovered from the path of this projectile.

Associated with the path of this projectile are 140 milliliters and 220 milliliters of liquid and clotted blood within the right and left chest cavities, respectively. The posterior aspect of the right fifth rib is fractured, as well as the sixth thoracic vertebrae. There is soft tissue hemorrhage of the structures involved and heavy laceration of the left lung.

The direction of the path of this projectile is right to left, back to front, and slightly downward.

Perforating Gunshot Wound "B" of the Head:

An entrance-type gunshot wound (labeled "9" in the diagrams and photographs) is 3 inches below the top of the head and 2 inches to the left of the posterior aspect of the midline on the posterior left aspect of the scalp. The 2.5 x 1.5 centimeter defect has no soot, stippling or abrasions associated with the wound.

The projectile perforated through the scalp and grazed across the posterior aspect of the left parietal bone, creating a 3 x 1 centimeter indentation/bony defect in this area. The projectile then exited the body through an exit-type gunshot wound (labeled "8" in the diagrams and photographs), 2-1/2 inches below the top of the head and 2 inches to the left of the posterior aspect of the midline on the posterior left aspect of the scalp. The 3.5 x 1.5 centimeter defect has a 0.3 centimeter abrasion from 9-12 o'clock. No soot or stippling is associated with this wound.

Associated with the path of this projectile is a small fracture in the left parietal bone. There is a thin area of subarachnoid blood underlying this bony defect in the left cerebral hemisphere towards the posterior aspect of the left parietal lobe. This area is approximately 5 x 5 centimeters. There is blood within the left ethmoid sinus.

The direction of the path of the projectile is slightly back to front, right to left, and upward.

Superficial Aggregate/Graze Wounds "C" of Right Shoulder:

An area of aggregate entrance-type gunshot wounds (labeled "7" in the diagrams and photographs) is 11-1/2 inches below the top of the head and 8 inches to the right of the posterior aspect of the midline on the posterior aspect of the right shoulder. The 1.5 x 1 centimeter defect has an 8 x 3 centimeter area of satellite wounds that radiate out from the 10-11 o'clock position of this defect. No soot is associated with this wound.

These wound tracks extend superficially into the underlying skin in this area; however, there are no projectile fragments that are recovered and this wound does not penetrate into the body cavity.

The direction of the path of these projectiles appears to be moving from a right to left direction.

Perforating Gunshot Wound "D" of the Right Thigh:

An entrance-type gunshot wound (labeled "3" in the diagrams and photographs) is 27 inches above the bottom of the right foot on the lateral aspect of the right thigh. The 1 x 0.8 centimeter defect has a 4 x 2 centimeter area of satellite abrasions that extend out 1.5 centimeters from the 5 o'clock position. No soot is associated with this wound.

The projectile perforated through the soft tissue, femur and vasculature of the right leg. The projectile appears to have fragmented and exited the body through two exit-type gunshot wounds (labeled "1" and "2" in the diagrams and photographs). The exit-type gunshot wound (labeled "1" in the diagrams and photographs) is 25-1/2 inches above the bottom of the right foot on the medial aspect of the right thigh. The 1.1 x 0.5 centimeter defect has a 0.1 centimeter laceration at 5 o'clock. No soot or stippling is associated with this wound.

An exit-type gunshot wound (labeled "2" in the diagrams and photographs) is 24 inches above the bottom of the right foot on the medial aspect of the right thigh. The 1.5 x 0.6 centimeter defect has a 0.3 centimeter laceration and abrasion at 9 o'clock. No soot or stippling is associated with this wound. No projectile fragments are recovered from the path of this projectile.

Associated with the path of this projectile is a fracture of the right femur, as well as lacerations of the vasculature of the right thigh.

The direction of the path of the projectile of right to left.

Having been mentioned above, these injuries will not be repeated below, except as needed for clarification.

INTERNAL EXAMINATION

The sternum and clavicles are intact. The diaphragm is not elevated. The mesothelial surfaces are smooth and glistening. All body organs are in their normal anatomic position. The right and left pleural cavities have no adhesions. The pericardial sac contains approximately 10 milliliters of yellow serous fluid. The peritoneal cavity has no excess fluid or adhesions.

The soft tissues of the neck, including strap muscles and large vessels, have no abnormalities. The hyoid bone, thyroid cartilage, and larynx are intact. The tan-brown thyroid gland has a normal size and shape, and homogenous, red parenchyma without nodularity. There is a 20 gram tan, homogenous thymus gland with unremarkable parenchyma.

The 200 gram heart has smooth epicardial surfaces and a normal amount of epicardial fat. The four cardiac chambers do not contain mural thrombi. The four thin, pliable cardiac valves have no deformities or vegetations. The mural endocardium is thin, smooth and translucent. The red-brown myocardium has no fibrosis, necrosis, erythema or areas of accentuated softening or induration. The normally positioned ostia of the left main and right coronary arteries are patent. The coronary arteries arise normally and follow a right dominant distribution. The left main, left anterior descending, left circumflex and right coronary arteries are thin-walled and patent. The left and right ventricles are 0.6 centimeters and 0.3 centimeters thick, respectively. The interventricular

septum is 0.7 centimeters thick. The thin, elastic aorta is smooth and shiny with intimal fatty streaking and no atherosclerosis.

The epiglottis is not edematous. The upper airway is clear of debris and foreign material. The mucosal surfaces are smooth, pink-gray, and unremarkable. The trachea and mainstem bronchi are clear of debris and foreign material. The right and left lungs are 220 grams and 180 grams, respectively. The pleural surfaces are smooth and glistening. The congested, red pulmonary parenchyma has no masses, granulomata or discrete areas of consolidation. The pulmonary arteries are patent and have no thromboemboli. The anthracotic bronchomediastinal lymph nodes are inconspicuous.

The 940 gram liver has a smooth, glistening, intact capsule covering dark brown parenchyma with a preserved lobular pattern. The liver has no focal lesions. The extra and intrahepatic vessels are patent. The gallbladder contains bile and no calculi. The gallbladder's mucosa is green and velvety. The cystic, common and hepatic bile ducts are patent.

The tongue is unremarkable. The esophagus is lined by gray-white smooth mucosa and is not dilated or stenosed and has no varices. The stomach has a normal size and shape. The gastric mucosa is free of ulcerations and is arranged with the usual folds. The stomach contains approximately 20 milliliters of tan-brown viscous liquid and partially digested food. The small intestine is normal in length, configuration and diameter and has a smooth, shiny serosal surface. The mucosa is free of ulcerations. The mesentery has a normal insertion. The large intestine has a smooth, shiny serosal surface and no palpable masses or obstructions. The appendix is present and unremarkable.

The pink-tan pancreas has an intact lobular architecture and patent duct.

The 70 gram spleen has an intact capsule covering red-purple, diffuent parenchyma. The bone marrow of the ribs has a soft consistency and is dark red. The lymph nodes of the neck, chest, abdomen and pelvis are inconspicuous.

The adrenal glands have yellow cortices and a brown medulla.

The right and left kidneys are 70 grams and 80 grams, respectively. The surfaces are red-brown and smooth. The parenchyma has well-defined corticomedullary junctions. The renal vessels are patent. The ureters have a normal course and caliber. The bladder contains 60 milliliters of urine. The mucosa is tan, mildly trabeculated and intact.

The vagina has a smooth mucosa and does not contain foreign material or obstructions. The cervix is free of nodules, masses, and erosions. The uterus is normal in size and shape and has no masses; no pregnancy is identified. The ovaries are tan-pink and normal in size. The fallopian tubes have no focal lesions.

The musculoskeletal system is well developed. The muscle groups of the anterior neck, chest wall, abdomen and iliopsoas are symmetrical, firm and red-brown. The pelvic bones and vertebral bodies of the cervical and lumbar spine are intact.

The reflected scalp has no hematomas. There is no epidural or subdural hemorrhage.

The brain is 1290 grams. The leptomeninges are thin and transparent. The cerebral hemispheres are symmetrical. The structures at the base of the brain, including cranial nerves and blood vessels, are intact. The thin-walled arteries at the base of the brain have no aneurysms or other obvious abnormalities. The gray/white matter border is distinct. The deep white matter has no softening, nodules or masses. The mammillary bodies are not shrunken or discolored. The dorsal cerebellar vermis is not atrophic. The symmetrical hippocampi are not shrunken, scarred or ecchymotic. The pituitary gland has a normal size. The atlanto-occipital ligaments and cervical spine are intact.

TOXICOLOGY: Blood, urine, and vitreous humor are submitted for toxicologic analysis (see separate report).

SUMMARY OF CASE

The decedent is a 28-year-old, assigned female at birth, reported transgender person who was identified by law enforcement as Audrey Hale and who was also known as Aiden. The decedent was witnessed to shoot three children and three adults during a mass shooting at The Covenant School in Nashville on March 27, 2023. Law enforcement arrived on scene and were witnessed to shoot the decedent, who was then pronounced dead at the scene.

The postmortem examination is significant for perforating and graze gunshot wounds of the body.

The toxicological analysis (basic profile) on the postmortem femoral blood did not detect drugs of abuse or ethanol.

Based on the circumstances and the collective findings, it is my opinion that the cause of death in this case is gunshot wounds; the manner is a homicide.

*****Electronically signed by Emily H. Dennison, M.D. on Thursday, June 8, 2023*****

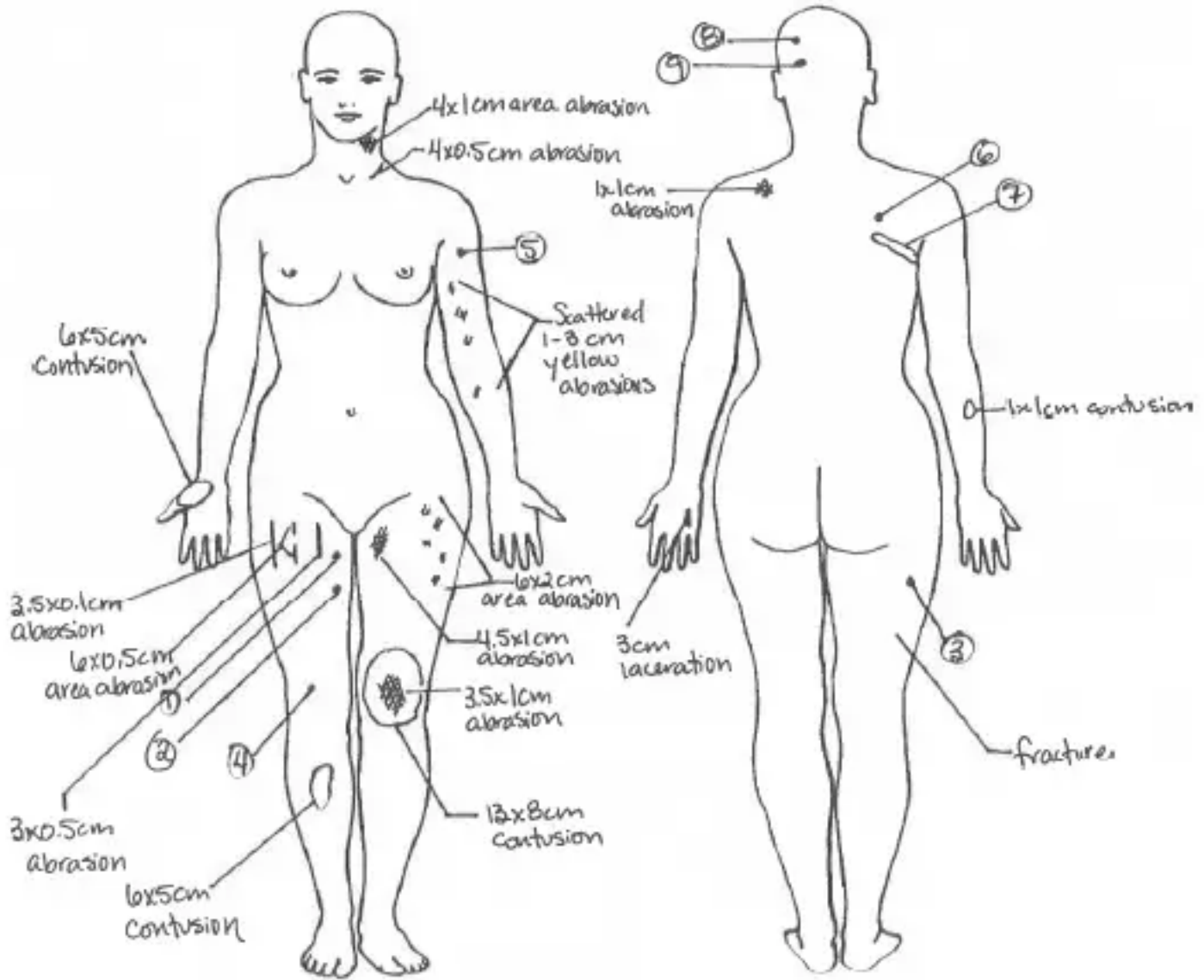
Emily H. Dennison, M.D.
Assistant Medical Examiner

EHD/pc
T: 4/15/2023



Name: Audrey/Aiden Hale MEC#: 23-1142

Injuries #1



ED



NMS Labs

CONFIDENTIAL

200 Welsh Road, Horsham, PA 19044-2208
Phone: (215) 657-4900 Fax: (215) 657-2972
e-mail: nms@nmslabs.com

Robert A. Middleberg, PhD, F-ABFT, DABCC-TC, Laboratory Director

Toxicology Report

Report Issued 04/11/2023 11:14

Patient Name HALE, AUDREY
Patient ID 23-1142
Chain NMSCP245711
DOB Not Given
Sex Female
Workorder 23122396

To: 10341
Forensic Medical Management Services - Nashville
850 R.S. Gass Blvd.

Nashville, TN 37216

Page 1 of 2

Positive Findings:

None Detected

See Detailed Findings section for additional information

Testing Requested:

Test	Test Name
8041B	Postmortem, Basic w/Vitreous Alcohol Confirmation, Blood (Forensic)

Specimens Received:

ID	Tube/Container	Volume/ Mass	Collection Date/Time	Matrix Source	Labeled As
001	Gray Stopper Glass Tube	9 mL	03/28/2023 19:49	Femoral Blood	23-1142
002	Red Stopper Glass Tube	3.75 mL	03/28/2023 19:49	Vitreous Fluid	23-1142
003	White Cap Plastic Container	60 mL	03/28/2023 19:49	Urine	23-1142

All sample volumes/weights are approximations.

Specimens received on 03/31/2023.



CONFIDENTIAL

Workorder 23122396
Chain NMSCP245711
Patient ID 23-1142

Page 2 of 2

Detailed Findings:

Examination of the specimen(s) submitted did not reveal any positive findings of toxicological significance by procedures outlined in the accompanying Analysis Summary.

Sample Comments:

001 Physician/Pathologist Name: EMILY DENNISON

Unless alternate arrangements are made by you, the remainder of the submitted specimens will be discarded one (1) year from the date of this report; and generated data will be discarded five (5) years from the date the analyses were performed.

Workorder 23122396 was electronically signed on 04/11/2023 10:32 by:

Chelsey N. Deisher, M.S., D-ABFT-FT
Forensic Toxicologist

Analysis Summary and Reporting Limits:

All of the following tests were performed for this case. For each test, the compounds listed were included in the scope. The Reporting Limit listed for each compound represents the lowest concentration of the compound that will be reported as being positive. If the compound is listed as None Detected, it is not present above the Reporting Limit. Please refer to the Positive Findings section of the report for those compounds that were identified as being present.

Test 8041B - Postmortem, Basic w/Vitreous Alcohol Confirmation, Blood (Forensic) - Femoral Blood

-Analysis by Enzyme-Linked Immunosorbent Assay (ELISA) for:

Analyte	Rpt. Limit	Analyte	Rpt. Limit
Amphetamines	20 ng/mL	Fentanyl / Acetyl Fentanyl	1.0 ng/mL
Barbiturates	0.040 mcg/mL	Methadone / Metabolite	25 ng/mL
Benzodiazepines	100 ng/mL	Methamphetamine / MDMA	20 ng/mL
Buprenorphine / Metabolite	0.50 ng/mL	Opiates	20 ng/mL
Cannabinoids	10 ng/mL	Oxycodone / Oxymorphone	10 ng/mL
Cocaine / Metabolites	20 ng/mL	Phencyclidine	10 ng/mL

-Analysis by Headspace Gas Chromatography (GC) for:

Analyte	Rpt. Limit	Analyte	Rpt. Limit
Acetone	5.0 mg/dL	Isopropanol	5.0 mg/dL
Ethanol	10 mg/dL	Methanol	10 mg/dL