

# Life-Saving Silicone Breast Implant After Firearm Injury: Case Report and Treatment Recommendations

Plastic Surgery Case Studies

Volume 6: 1-5

© 2020 The Author(s)

Article reuse guidelines:

[sagepub.com/journals-permissions](https://sagepub.com/journals-permissions)

DOI: 10.1177/2513826X19898821

[journals.sagepub.com/home/pcs](https://journals.sagepub.com/home/pcs)

Giancarlo McEvenue, MD<sup>1</sup> , Anastasia Oikonomou, MD<sup>2</sup>,  
Noah Ditzkofsky, MD<sup>2</sup>, and Joan Lipa, MD<sup>2</sup>

## Abstract

Breast augmentation with silicone implants is one of the most commonly performed operations by plastic surgeons. Here, we report a case of a 30-year-old female patient with a ballistic injury to bilateral breast implants, where the silicone implant was likely responsible for deflecting the bullets trajectory and saving the women's life. Ballistics analysis of bullet trajectory was performed with high-resolution computed tomography scan analysis. Operative management was implant removal, pocket irrigation, and a short course of antibiotics. A literature review was performed on all previously published breast implant-related firearm injuries. The authors advise operative management with implant removal and delay of replantation for minimum 6 months' time.

## Keywords

ballistics, firearm, gunshot injury, bullet, thoracic injury, thoracic trauma, breast implant, breast augmentation

## Introduction

Breast augmentation is one of the most commonly performed operative procedures done by plastic surgeons. The American Society of Plastic Surgeons reports that in 2016 alone over 290 000 women had breast augmentation.<sup>1</sup> Due to their low-risk profile and well-published benefits on quality of life and body image, many millions of women currently have breast implants.<sup>2,3</sup> Surgeons who perform breast implant operations must discuss the risks and benefits of breast implants with all patients prior to the operation. The benefits of breast augmentation are generally accepted to be on quality of life, as until recently implants had never been considered life saving. Risks are always discussed with patients, and one rarer risk that is increasingly being discussed due to it being potentially fatal is the risk of breast implant-associated anaplastic large cell lymphoma (BIA-ALCL).<sup>4</sup> The risk of BIA-ALCL is currently estimated to be between 1: 1000 and 1: 30 000 for patients with textured devices.<sup>5</sup> Gun violence is also a rare risk that women face, where according to the Centers for Disease Control in the United States, the rate of non-fatal firearm injuries was 4.94 per 100 000 women.<sup>6</sup> In Canada, Statistics Canada reports

that there were 41 female homicides by firearm in 2015.<sup>7</sup> Interestingly, despite the millions of women with breast implants and the thousands of women affected by gun violence worldwide, ruptured implants after firearm injury is a rarely reported phenomenon in the literature, with only several case reports having been described previously.<sup>8,9</sup> Rosen et al were the first to show that breast implants can save a life with a case of a silicone implant stopping shotgun pellet.<sup>10</sup> Pannucci et al were the first to detail a report of a saline breast implant saving a patient's life due to effects on bullet velocity.<sup>11</sup> Here, we report the first case in the literature of a 30-year-old female patient with silicone breast implants altering bullet trajectory and thereby saving her life. We also perform a literature review and provide treatment recommendations.

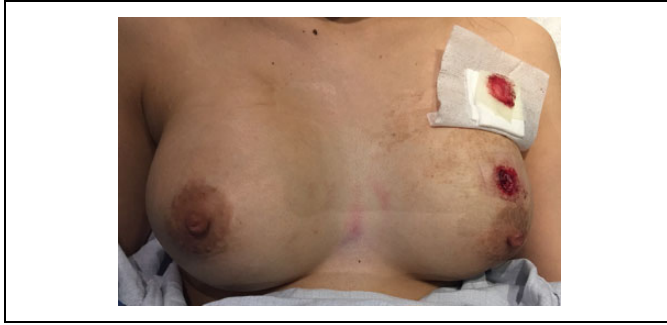<sup>1</sup> McLean Clinic, Mississauga, Ontario, Canada

<sup>2</sup> Sunnybrook Health Sciences Center, Toronto, Ontario, Canada

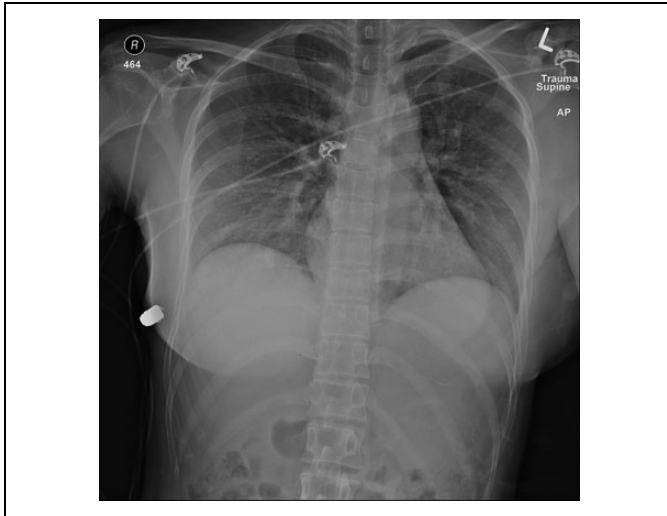
### Corresponding Author:

Giancarlo McEvenue, Education and Research, The McLean Clinic, 50 Burnhamthorpe Road West, Suite 343, Mississauga, Ontario, Canada L5B 3C2.  
Email: [g.mcevenue@utoronto.ca](mailto:g.mcevenue@utoronto.ca)

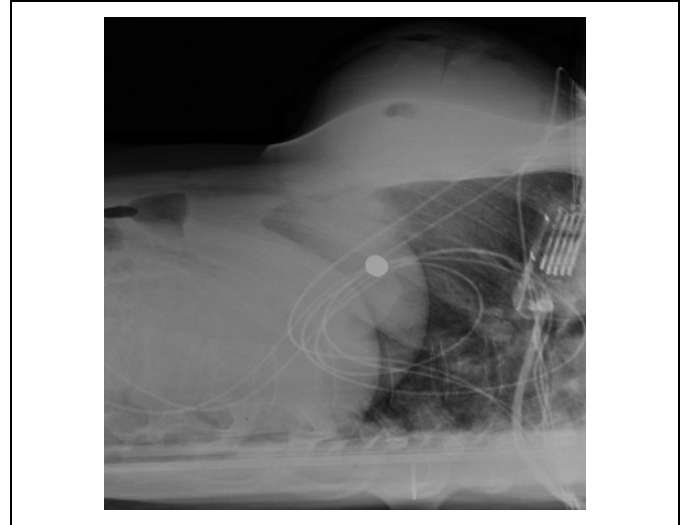




**Figure 1.** Anterior view of the chest showing bullet entrance wound in superior left breast.



**Figure 2.** Anteroposterior (AP) and lateral chest radiographs. Note bullet in right lateral thoracic wall on AP chest X-ray. Note gas along bullet trajectory in lateral view.



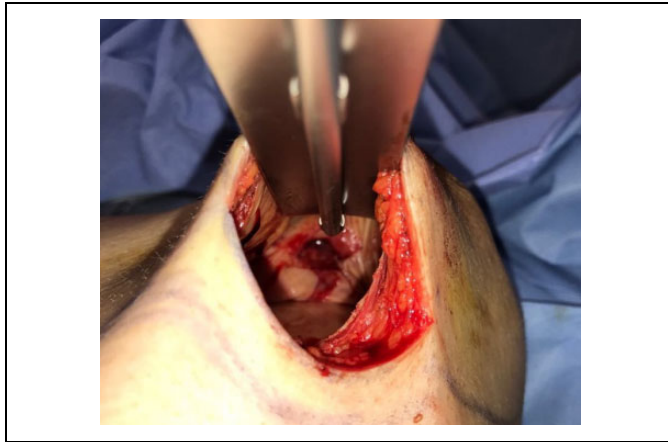
**Figure 3.** Anteroposterior (AP) and lateral chest radiographs. Note bullet in right lateral thoracic wall on AP chest X-ray. Note gas along bullet trajectory in lateral view.

give clues to the bullet's trajectory from left breast entrance to right thoracic wall resting place. A computed tomography (CT) scan was obtained which revealed areas of pulmonary contusion but no intrathoracic injury. In the left-sided breast implant, there was debris and air. There was also some air noted in the right breast implant. The patient was evaluated and cleared by our trauma service.

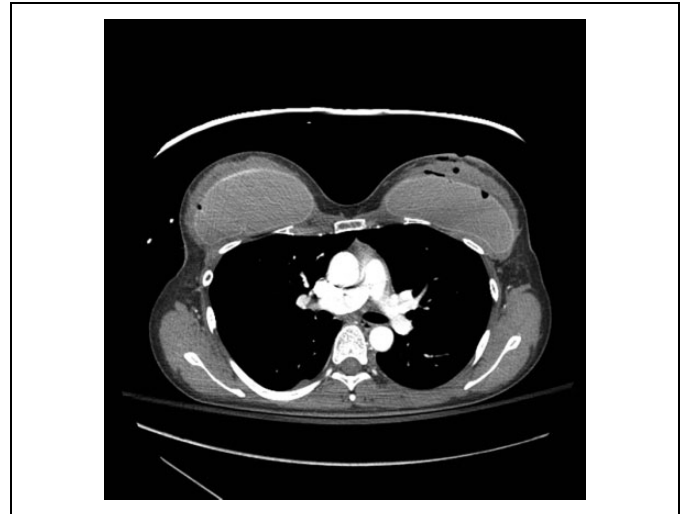The surgical plan was to remove the implants via bilateral 5-cm incisions in the inframammary folds. This approach would provide maximal exposure of the implants, pockets, and any areas of injury. On the right side after dissecting through skin, we came upon a subcutaneous hematoma continuous with the breast capsule and tracking subcutaneously and inferolaterally toward the bullet. We used blunt dissection to follow the hematoma along this tunnel and retrieve the bullet which was handed off to police services and sent for forensics. The bullet was determined to be copper jacketed 0.40 caliber by the police services. Next, we performed bilateral capsulotomies that revealed hematoma surrounding both breast implants. The left implant was removed first. Upon examination of this implant, a bullet tract was found beginning directly underlying the entry wound in the right breast (Figure 4). This bullet tract tracked through the implant exiting from the medial aspect of it (Figure 5) and at this point penetrated the capsule and went through the parasternal tissues and presternal tissues, entering the right breast implant pocket. At this point, we removed the right breast implant, which was found to be in a completely flipped position, with the posterior aspect of the implant riding superficially. The area of damage on the right breast implant (Figure 6) was at the dome of the implant. The right breast capsule had a medial rent within the capsule, and there was tracking of the bullet tract along the chest wall tissues in the region of the intercostal muscles tracking posterior to the posterior capsule, and then exiting out in the inferolateral

## Case Presentation

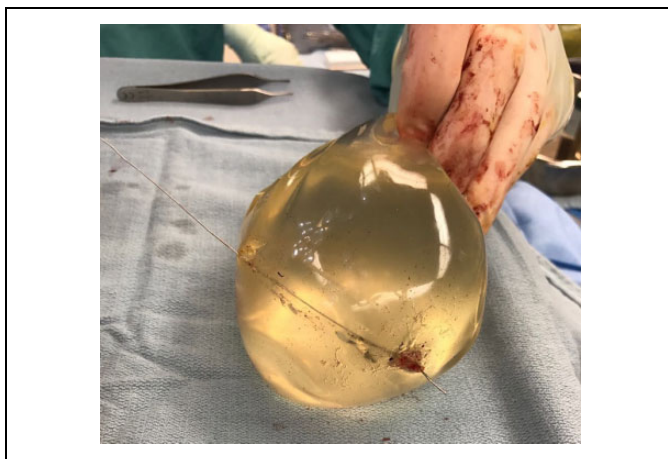A 30-year-old woman with a history of subpectoral silicone breast implants placed through a periareolar incision (450 mL smooth round) was seen by the trauma service for evaluation of penetrating chest trauma due to gunshot wound. The events of the evening are the subject of investigation. The patient reported walking down street and feeling heat and pain in her left chest, looking down and seeing blood, and taking herself into the local emergency department. The firearm was never recovered, and the shooter remains unknown. The patient was transferred to our trauma center in stable condition with no additional injuries. Clinical examination revealed a comfortable patient in no distress with a single entry wound in the superior pole of the left breast (Figure 1). The entry wound demonstrated thermal injury surrounding the bullet hole indicating a close proximity to the discharging firearm. A hard, subcutaneous, bullet-like mass was also palpable in the right lower anterior thoracic wall inferior to the right breast. Trauma radiographs (Figures 2 and 3) demonstrate the radio-opaque bullet in the right lateral thoracic wall, a fractured rib and gas in the left breast. These 3 pieces of evidence



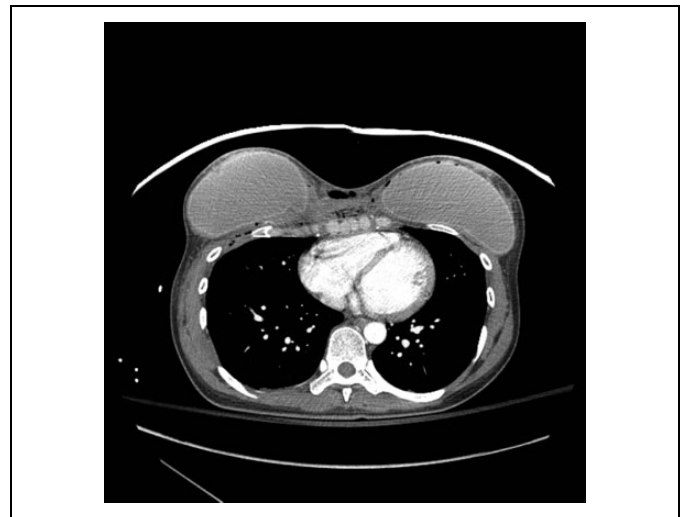**Figure 4.** Intraoperative view of left breast capsule with implant removed showing bullet wound anteriorly.



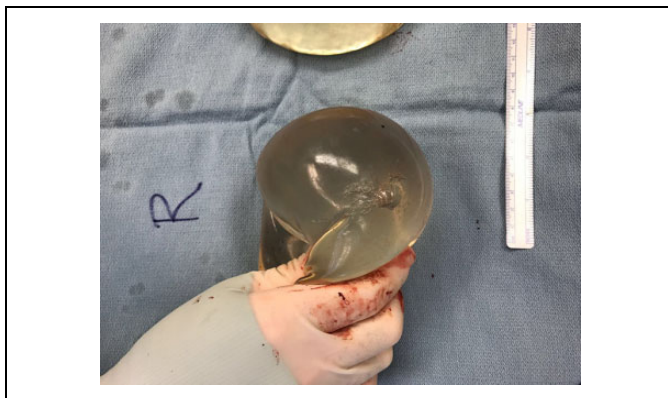**Figure 7.** Axial computed tomography (CT) scan revealing entry wound to left breast with bullet tract into left breast implant, hematoma, and soft tissue damage.



**Figure 5.** Intraoperative view of left breast implant showing bullet trajectory through implant.



**Figure 8.** Axial computed tomography (CT) scan revealing bullet tract across midline, anterior to sternum, and entering into the right breast capsule.

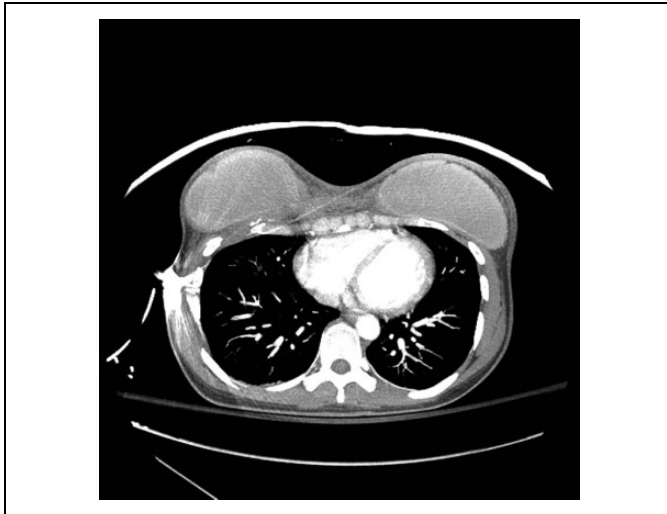

**Figure 6.** Intraoperative view of right breast implant with damage from bullet trajectory.

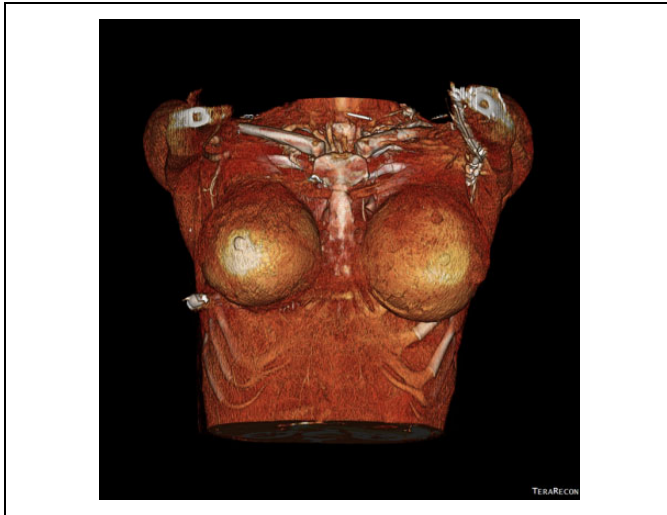
subcutaneous and breast tissue and then traversing to the right lateral chest wall region where we had previously located the bullet. We irrigated both pockets copiously with normal saline and betadine. We then closed the capsule and areas of damage

in layers over drains. The entry wound was debrided conservatively and treated with daily wound care.

Postoperatively, ballistics analysis was performed using helically acquired 0.625-mm axial CT (Figures 7–9) images with multiplanar and 3D reformats (Figures 10 and 11) in conjunction with clinical assessment of the surface wounds. Reconstructed maximal intensity projections images demonstrate the bullet exit from the left implant to the posterior aspect of the right implant. Also revealed is the bullet in the right thoracic wall. Based on trajectory of bullet entry clinically and evaluation radiologically, the only source of bullet deflection of the bullet is the left breast implant. This implant overlies the heart and intrathoracic cavity and therefore likely saved the women’s life. There is a contact wound to thoracic wall based

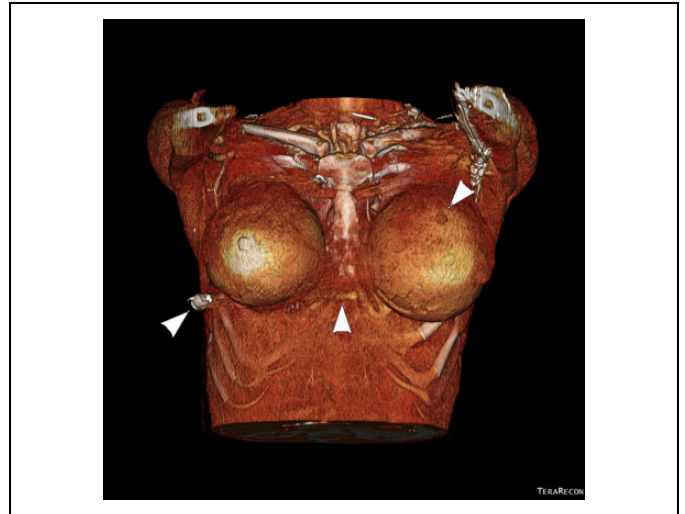


**Figure 9.** Axial computed tomography (CT) scan showing final bullet resting position with artifact and rib fracture on right side of chest.



**Figure 10.** 3-dimensional (3D) reformatted volume-rendered image of chest with subcutaneous tissues removed (except nipples for anatomic reference).

on cavitation of soft tissues and charring of skin at the entry wound. Clinically, the tract was palpable and headed straight from anterior to posterior through the chest wall; however, on radiograph the bullet was not where expected. It had been deflected and was resting in the right anterior chest subcutaneously. The CT scan views show the bullet tract that correlates clinically with the level of breast implant. Examination of the axial CT shows the transverse tract that can clearly be seen crossing the midline. Consequently, a deflection must have occurred. The only source of deflection is the patient's silicone implant. On clinical examination of the removed implant (Figure 5), an oblique tract through the implant lines up with both tracts across the chest wall. This indicates that deflection occurred within the implant likely at the point of the bullet pressing in on and rupturing the implant membrane. Both



**Figure 11.** 3-dimensional (3D) reformatted volume-rendered image with arrows. Image demonstrates left breast entry wound (right arrow), tract of bullet with disruption of presternal soft tissues (middle arrow), and bullet in right lateral chest wall (left arrow).

clinical and radiologic evidence support this theory of bullet deflection.

## Literature Review

A PubMed search was performed in the English language using the search terms: "implant," "breast," "gunshot," and "firearm." Four papers were found, and the details are summarized in Table 1. In all papers reviewed, the patient survived the gunshot injury. The majority (3/4) involved silicone implants. Half (2 of 4) of treating surgeons decided to immediately replace the implants. The implants likely played a role in saving the patient's life according to the authors in 2 of the 4 reports. None of the reports reviewed offered treatment recommendations.

## Discussion

Based on our review of the literature, there are surprisingly few cases of breast implants ruptured due to firearm injury published in the literature. Given the high number of women with implants and the relatively high numbers of gun violence in the United States, the authors believed there would be more than the 4 previously published cases found. Our report represents the fifth reported and the third, where the implant is believed to be responsible for saving the patient's life. Although rare, these observations lend support to the hypothesis that indeed breast implants can save lives. This hypothesis was elegantly tested in the article by Pannucci et al<sup>11</sup> who measured gel penetration of bullets after passing through implants or not. Our study adds to this knowledge by using high-resolution CT technology to analyze bullet trajectory in an actual patient case. This trajectory change could only have been due to the bullet hitting the implant in our patient's case, as the bullet did not hit bone on the left side (as evidenced by lack of left-sided fracture and a bullet that retained enough energy to cause right-sided

**Table 1.** Literature Review.

First Author	Title	Year	Study Type	Patients	Implant Type	Surgical Management	Adjuncts
Pramod	Breast Implant Rupture Due to Gunshot Injury	1994	Case report	1	Silicone	Debridement, explantation, irrigation	Drains
Periera	Rupture of High-Cohesive Silicone Implant After Gunshot Injury	2007	Case report	1	Silicone	Debridement, Implant exchange	None
Rosen	Silicone Breast Implants Can Save Lives	2014	Case report	1	Silicone	Debridement, implant exchange	None
Panucci	A Ballistics Examination of Firearm Injuries Involving Breast Implants	2017	Case report, ballistics, experiment	1	Saline	Debridement, explantation	None

fractures). This means the implant is the cause of the change in the bullets trajectory.

Treatment of ruptured implants due to ballistic injury should be similar to the treatment of an infected/ruptured implant. Research on contamination of bullet wounds lends support to considering all gunshot wounds as potentially contaminated.<sup>12</sup> We therefore recommend removal of the implants, irrigation of the pocket, and not replacing the implant until all potential infection has resolved. The use of drains and antibiotics was used in our case due to the delayed time until presentation and high degree of localized tissue damage. We recommend using these adjuncts when there is a higher degree of contamination, higher velocity weapon involved, or a delay in time until debridement. The amount of debridement necessary will vary based on degree of injury and amount of devitalized tissues. Limitations of our literature review are that there may be cases published in the non-English literature. Another limitation may be the patients who do not survive the firearm injury and go unreported.

In conclusion, we report here the case of a 30-year-old woman whose life was likely saved by deflection of the bullet by her silicone implants. Our analysis of bullet trajectory to show the implant doing this is the first of its kind in the literature. Furthermore, after reviewing the literature, we recommend removal of the implants after firearm-related injury and management of the implant pocket as potentially contaminated.

### Statement of Human and Animal Rights

This article does not contain any experimental studies with human or animal subjects.

### Statement of Informed Consent

Written, informed consent was obtained from the patient included in this case report.

### Declaration of Conflicting Interests

The author(s) declared no potential conflicts of interest with respect to the research, authorship, and/or publication of this article.

### Funding

The author(s) received no financial support for the research, authorship, and/or publication of this article.

### ORCID iD

Giancarlo McEvenue, MD  <https://orcid.org/0000-0001-7817-1844>

### References

1. American Society of Plastic Surgeons. *2016 Plastic Surgery Statistics Report*, 2017. <https://d2wirczt3b6wjw.cloudfront.net/News/Statistics/2016/2016-plastic-surgery-statistics-report.pdf>. Accessed March 28, 2020.
2. McCarthy CM, Cano SJ, Klassen AF, et al. The magnitude of effect of cosmetic breast augmentation on patient satisfaction and health-related quality of life. *Plast Reconstr Surg*. 2012;130(1):218-223.
3. Alderman AK, Bauer J, Fardo D, Abrahamse P, Pusic A. Understanding the effect of breast augmentation on quality of life: prospective analysis using the BREAST-Q. *Plast Reconstr Surg*. 2014;133(4):787-795.
4. Clemens MW, Miranda RN, Butler CE. Breast implant informed consent should include the risk of anaplastic large cell lymphoma. *Plast Reconstr Surg*. 2016;137(4):1117-1122.
5. Loch-Wilkinson A, Beath KJ, Knight RJW, et al. Breast implant-associated anaplastic large cell lymphoma in Australia and New Zealand: high-surface-area textured implants are associated with increased risk. *Plast Reconstr Surg*. 2017;140(4):645-654.
6. Centers for Disease Control and Prevention. *Web-Based Injury Statistics Query and Reporting System*, 2018. [www.cdc.gov/injury/wisqars/facts.html](http://www.cdc.gov/injury/wisqars/facts.html). Accessed March 28, 2020.
7. Statistics Canada. *Table 3 Homicide Victims and Accused Persons, by Aboriginal Identity and Sex*; 2016. <http://www.statcan.gc.ca/daily-quotidien/161123/t003a-eng.htm>. Accessed March 28, 2020.
8. Pramod NK, Thoma A. Breast implant rupture due to gunshot injury. *Plast Reconstr Surg*. 1994;94(6):893-894.
9. Pereira LH, Sterodimas A. Rupture of high-cohesive silicone implant after gunshot injury. *Ann Plast Surg*. 2007;58(2):228-229.
10. Rosen H, Brzeziński M, Higdon KK. Silicone breast implants can save lives. *Plast Reconstr Surg Glob Open*. 2014;2(6):e169.
11. Pannucci CJ, Cyr AJ, Moores NG, Young JB, Szegedi M. A ballistics examination of firearm injuries involving breast implants. *J Forensic Sci*. 2017;63(2):1-6.
12. Santucci RA, Chang YJ. Ballistics for physicians: myths about wound ballistics and gunshot injuries. *J Urol*. 2004;171(4):1408-1414.