

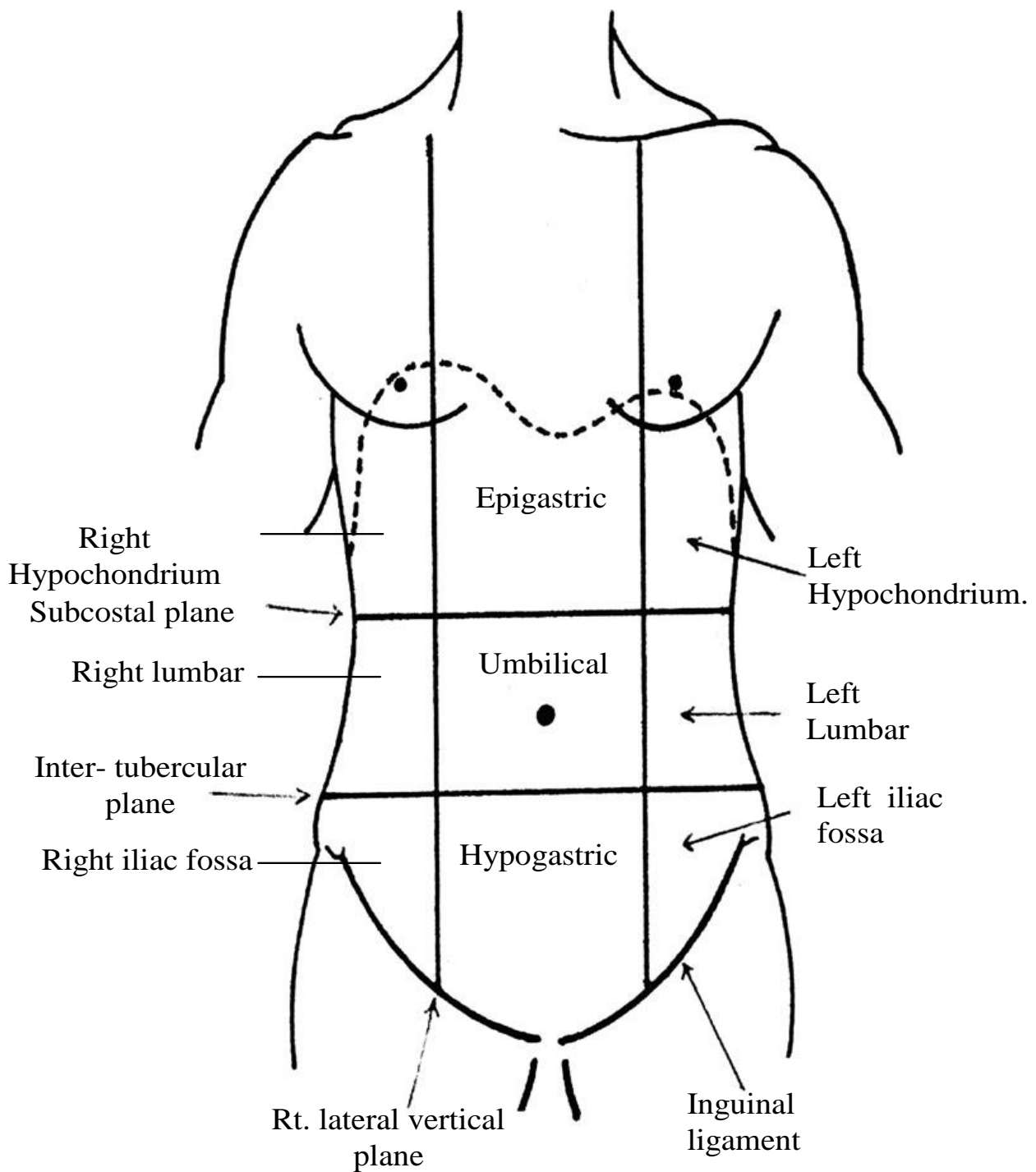
Planes of The Abdomen

- 1. Transpyloric Plane:** It lies midway bet. the suprasternal notch & symphysis pubis or hand breadth below the xiphisternal junction(level of L1 vertebra). It passes through the pylorus, beginning of duodenum, fundus of G.B, upper border of neck of pancreas, body of pancreas, origin of sup. mesenteric artery, hilum of kidney, epiploic foramen, tip of 9th costal cartilage, upper end of linea semilunaris, lower end of spinal cord, body of L1 vertebra.
- 2. Subcostal plane:** at the level of lowest point of costal margins (level of L3 vertebra).
- 3. Intertubercular plane:** passing through the tubercles of iliac crests (level of L5 vertebra).
- 4. Rt. & Lt. lateral Vertical planes:** 2 vertical planes passing from mid-clavicular to mid-inguinal points (passing just med. to the nipple & at the lat. border of rectus muscle i.e. linea semilunaris).

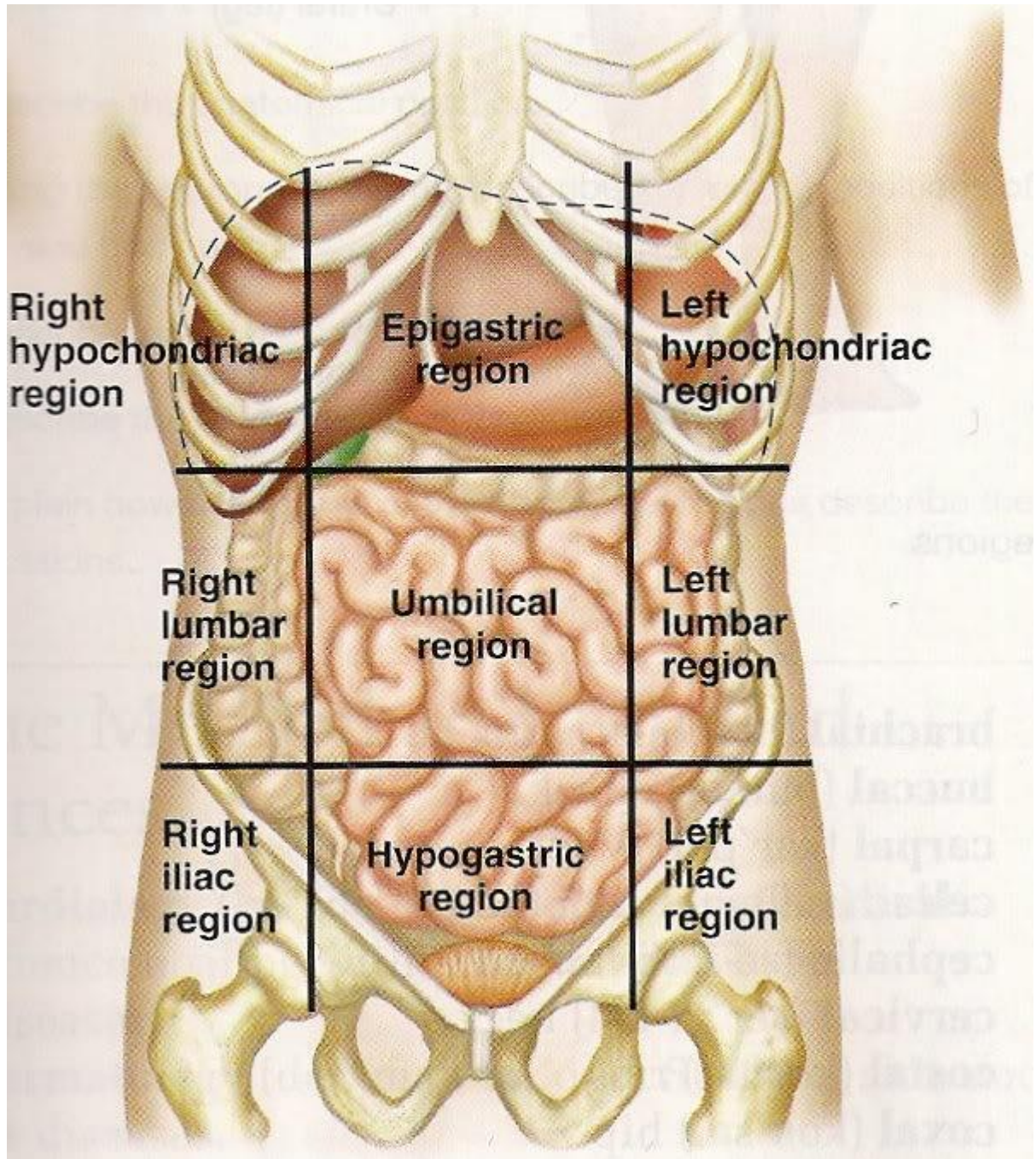
Regions of The Abdomen

* The abdomen is divided into 9 regions by 2 vertical planes (2 lat. vertical planes) & 2 horizontal planes (subcostal & intertubercular planes).

- | | |
|-----------------------|-------------------------------|
| 1. Rt. Hypochondrium | 2. Epigastrium. |
| 3. Lt. hypochondrium. | 4. Rt. Lumbar |
| 5. Umbilical. | 6. Lt. lumbar. |
| 7. Rt. iliac fossa | 8. Suprapubic (hypogastrium) |
| 9. Lt. iliac fossa. | |



*** Planes & Regions of the Abdomen ***



Right		Left
Gallstones Stomach Ulcer Pancreatitis	Stomach Ulcer Heartburn/ Indigestion Pancreatitis, Gallstones Epigastric hernia	Stomach Ulcer Duodenal Ulcer Biliary Colic Pancreatitis
Kidney stones Urine Infection Constipation Lumbar hernia	Pancreatitis Early Appendicitis Stomach Ulcer Inflammatory Bowel Small bowel Umbilical hernia	Kidney Stones Diverticular Disease Constipation Inflammatory bowel disease
Appendicitis Constipation Pelvic Pain (Gynae) Groin Pain (Inguinal Hernia)	Urine infection Appendicitis Diverticular disease Inflammatory bowel Pelvic pain (Gynae)	Diverticular Disease Pelvic pain (Gynae) Groin Pain (Inguinal Hernia)

D.D of Abdominal pain