

Ocular Trauma

Nathan Lambert, MD
Ophthalmology Resident
Casey Eye Institute



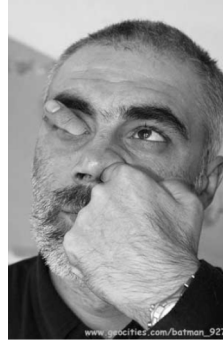Bad things happen...



...sometimes it's his fault

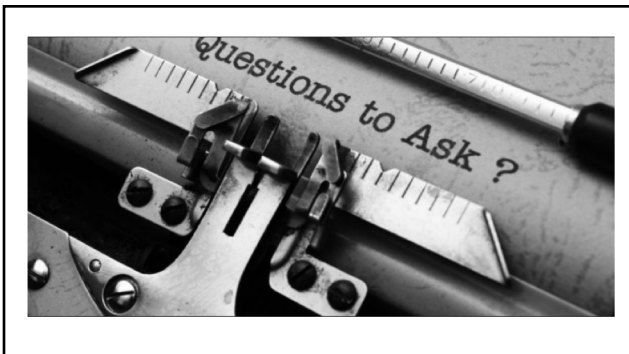
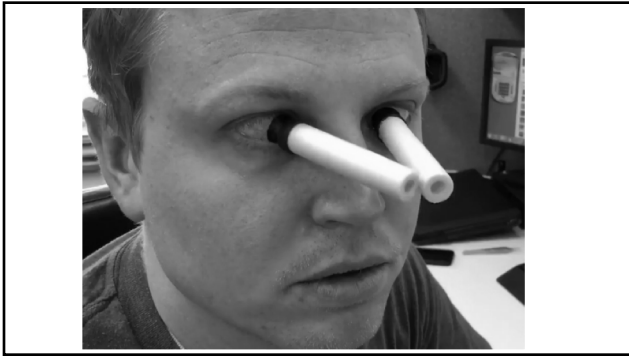
Sometimes it's your fault...




Sometimes it's the other guy's...





Objectives

- Understand different types of ocular trauma
- Understand how to triage ocular injuries
- Know what to tell people to do, and when to be evaluated



Bad eye injury in
3...2...1..

24 year old Female...

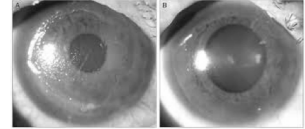
- Contact lens wearer
- Woke up with pain, redness, blurry vision, and light sensitivity

Ddx:

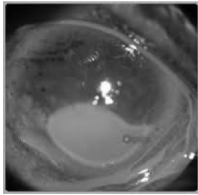
Kahoot #1

Epithelial Defect

- 24 year old Female
- Contact lens wearer
- Woke up with pain, redness, blurry vision, and light sensitivity



Epithelial Defect

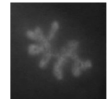
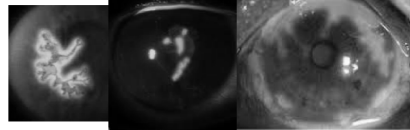


- Fluorescein highlights the defect
- Numbing agent reduces the pain significantly

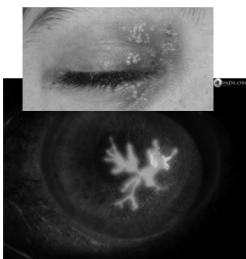
Ddx: corneal epithelial defect vs ?

Differential diagnoses to consider...

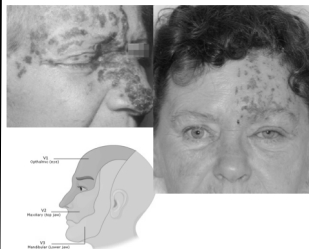HERPES (HSV, VZV)



Herpes Simplex (HSV)

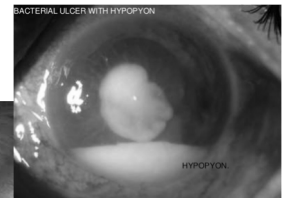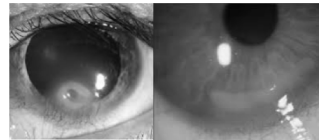


Herpes Zoster (VZV)



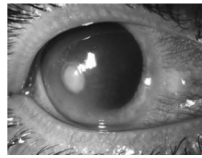
Differential diagnoses to consider...

- CORNEAL ULCER =
- Epi defect + Infiltrate/stromal haze
 - Bacterial >>> fungal



Can have hypopyon in severe cases

Corneal Ulcers



Culture

- BEFORE starting antibiotics

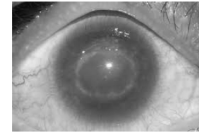
TREATMENT

- Topical antibiotics (fluoroquinolone)
 - Ofloxacin/Ciprofloxacin
 - Vigamox (Moxifloxacin)
- If LARGE (2mm) or CENTRAL – start FORTIFIED antibiotics
 - Vancomycin and Tobramycin

Acanthamoeba

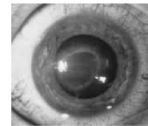
SIGNS/SYMPTOMS:

- SEVERE eye pain (out of proportion)
- History of mountain water exposure
- Consider in any patient with soft contact use
- Redness, photophobia over weeks
- Later – ring shaped stromal infiltrate



DIAGNOSIS:

- Bacterial cultures are NEGATIVE
- Cysts on confocal microscopy



TREATMENT

- Does NOT respond to antibiotics
- Chlorhexidine

Epithelial Defect

QUESTIONS

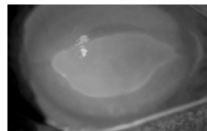
- Contact lens use?
- Trauma?
- Foreign body?
- Rash?

EXAM

- Fluorescein (distribution?)
- Facial Rash
- Infiltrate

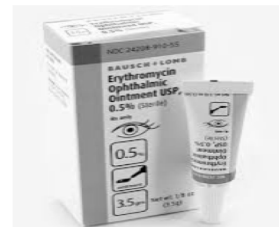Ddx:

- Abrasion
- Herpetic
- Ulcer



Regular ol' Epithelial defect

- Mainstay of treatment is erythromycin ointment.
- Never start with a steroid, avoid Maxitrol.



40 year old male...

- Janitor at school
- Got some cleaning material in eye
- Pain and blurry vision

Kahoot #2

What should he do next?

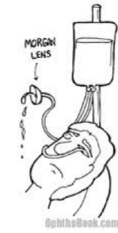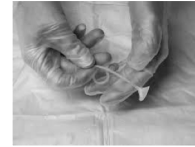CHEMICAL BURN

CALL

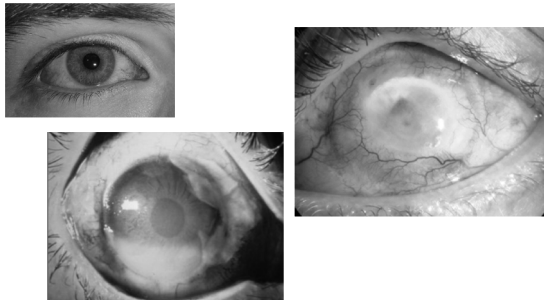
- 40 year old M, janitor at school
- Got some cleaning material in eye

History

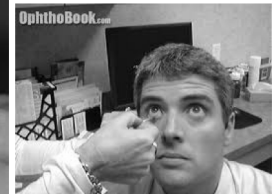- What chemical?
- When was exposure?



ADVICE?
RINSE
RINSE
RINSE
RINSE

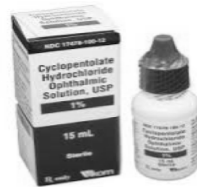

pH strips



Chemical Burn-- Treatment

- Mild to moderate: Erythromycin Q1-2 hours
- +/- Cycloplegic
- +/- IOP lowering therapy if indicated
- Severe: may also require topical steroids
- +/- topical abx gtt
- +/- BCL, pressure patch
- Consider:
 - Oral Doxycycline 100 mg PO BID
 - Vitamin C 1000 mg daily
- Follow up: daily initially



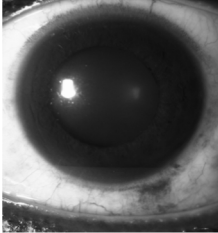
Chemical Burn

QUESTIONS

- When?
- What?

RINSE!!!

Kahoot #3

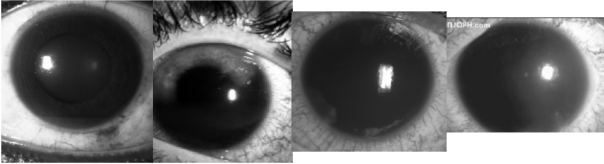


9 year old boy...


- Playing NERF wars with brother
- Nerf arrow shot him in the eye
- Pain in the eye, very light sensitive, vision is “kinda blurry”

Hyphema

- 9 year old boy playing NERF wars with brother – nerf arrow shoot him in the eye
- Pain in the eye, very light sensitive, vision is “kinda blurry”



Hyphema Treatment




- Keep head elevated
- No Aspirin, Ibuprofen, blood thinners
- Consider sickle prep– assess risk
- Shield– protect the eye
- Cycloplegic for pain
- Bed rest!
- Close follow up (daily initially)
- High risk of re-bleed!
- May require surgical evacuation if not resolving, IOP spike occurs, or corneal blood staining occurs

Hyphema

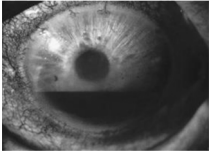
QUESTIONS

- Mechanism of trauma?
- Photophobia
- Potential foreign body?
- Flashes/Floaters?
- Sickle cell disease?




EXAM

- Ruptured globe?
- How tall hyphema?
- Eye Pressure!




Subconjunctival Hemorrhage

Patient calls in and says “My eye bleeding!”



Questions to ask:

- Pain?
- Redness (the white part? Or there is blood coming from eye?)
- Hx/o trauma? Prev surgery?



Risk Factors

- Blood thinners
- Age
- High blood pressure
- Coughing
- Valsalva

Often resolve over
2-3weeks

Kahoot


60 year old Female...

Woke up and noticed eye was “all red”!

- History of atrial fibrillation and high blood pressure
- Currently has an upper respiratory infection
- No change to vision
- No pain, irritation, or light sensitivity
- No recent trauma
- No previous surgery

Subconjunctival Hemorrhage

Patient calls in and says "My eye bleeding!"




Questions to ask:

- Pain?
- Redness (the white part? Or there is blood coming from eye?)
- Hx/o trauma? Prev surgery?


Risk Factors

- Blood thinners
- Age
- High blood pressure
- Coughing
- Valsalva

Often resolve over 2-3weeks




Corneal metallic foreign body



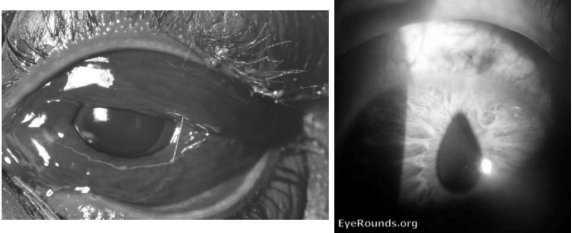
Corneal metallic foreign body

- Mechanism of injury
- Size, weight, velocity, force of object
- Document VA *before* any procedure is performed
- Check under lids!



Kahoot


These are two findings of ...?



Kahoot

35yo M, construction worker...


- Using nail gun, when...



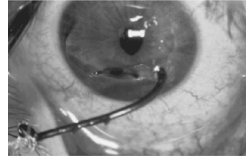
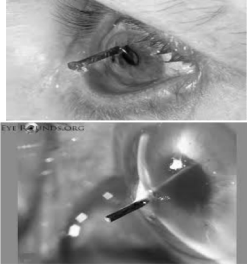
Ruptured Globe

35yo M, construction worker...

- Using nail gun, when...



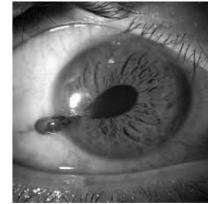
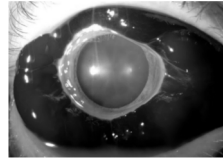
Penetrating globe injury



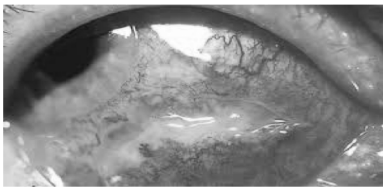
Do NOT remove

...need operating room

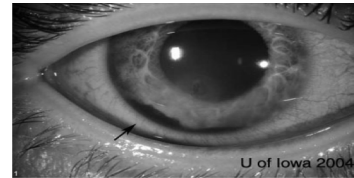
Ruptured globe – not so obvious



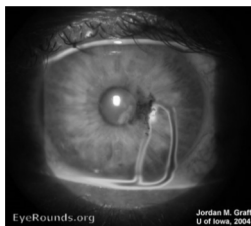
Ruptured globe – check the conjunctiva



Ruptured globe – check the limbus




Ruptured globe – check cornea



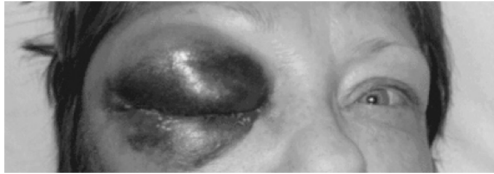
Ruptured Globe Initial Response

- CT Head/orbits
- IV Antibiotics (400 mg IV Moxifloxacin preferred– best vitreous penetration)
- Shield
- Tetanus
- Antiemetic
- Pain control
- Rest
- NPO!
- Call for urgent surgical evaluation



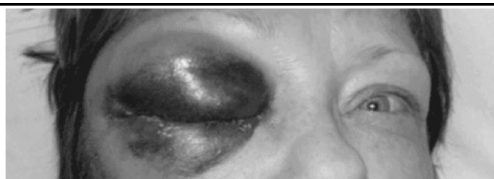
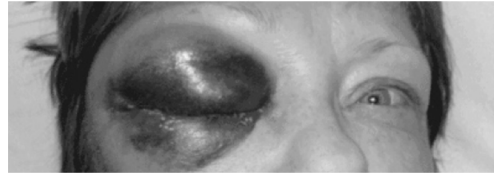
Kahoot

69yo Female, falls while walking up the stairs to your clinic...



Retrobulbar hemorrhage

69yo Female, falls while walking up the stairs to your clinic...

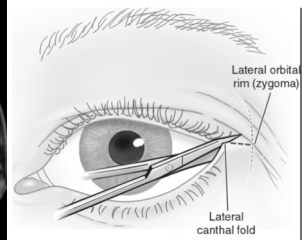
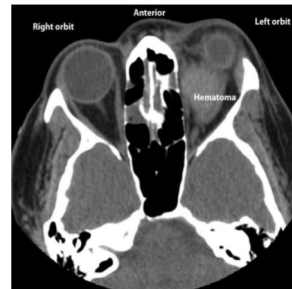

QUESTIONS

- Mechanism of trauma?
- Blood thinners?
- Flashes/Floaters?

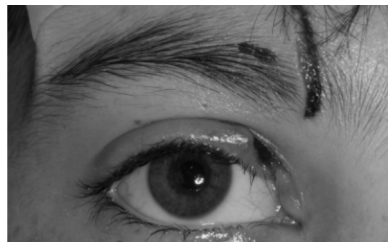EXAM

- Ruptured globe?
- Afferent pupillary defect (APD)
- Motility
- Eye Pressure

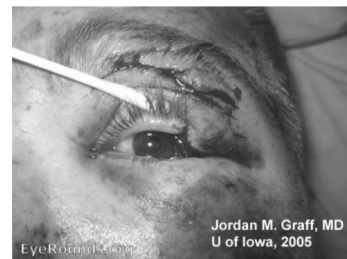

Kahoot

10 year girl...
•dog bite to face...

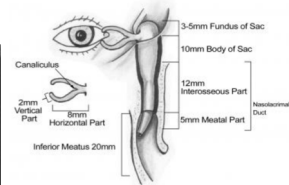
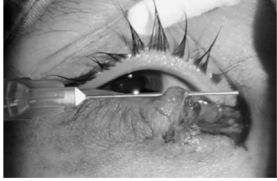


Eyelid laceration



Jordan M. Graff, MD
U of Iowa, 2005

Eyelid laceration



EXAM

- Ruptured globe?
- Motility
- Canalicular involvement

QUESTIONS

- Mechanism of trauma? (dog bite, fall, knife, etc)
- Double vision?

Conclusion

- Eye injuries can occur in a variety of ways
- Important to know how triage ocular injuries
- Know what to tell people to do, and when to be evaluated

