

UNIVERSITY OF IOWA
HEALTH CARE

*Department of Ophthalmology
and Visual Sciences*


Cool cases

Thomas A Oetting
University of Iowa

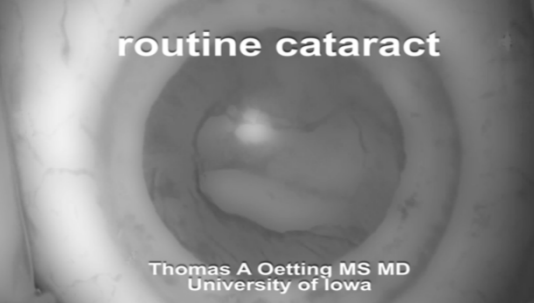
No Financial Issues to Disclose

1

1




2



routine cataract

Thomas A Oetting MS MD
University of Iowa

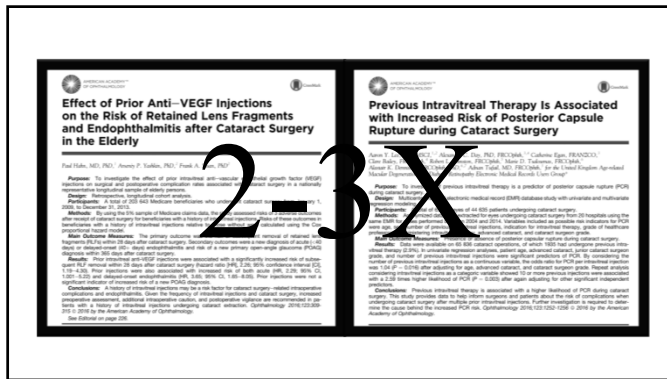
3

A black and white photograph of a toilet bowl. The bowl is dark and circular, surrounded by a lighter-colored rim. The text "what now?" is written in white, lowercase letters in the upper center of the bowl, and "why me?" is written in white, lowercase letters in the lower center of the bowl. The entire image is framed by a thick black border.

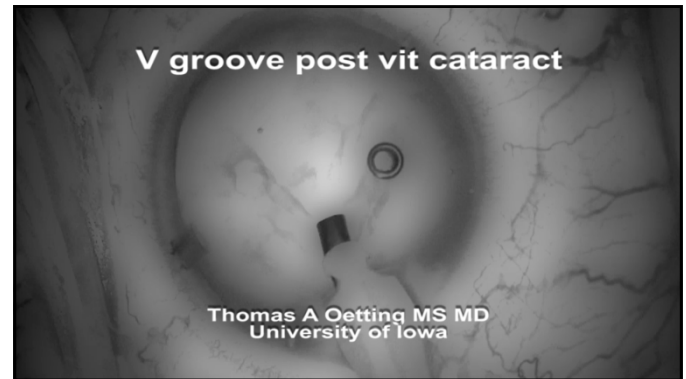
4

5

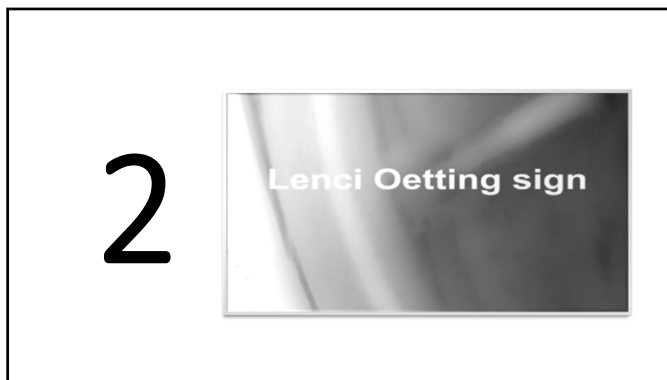6



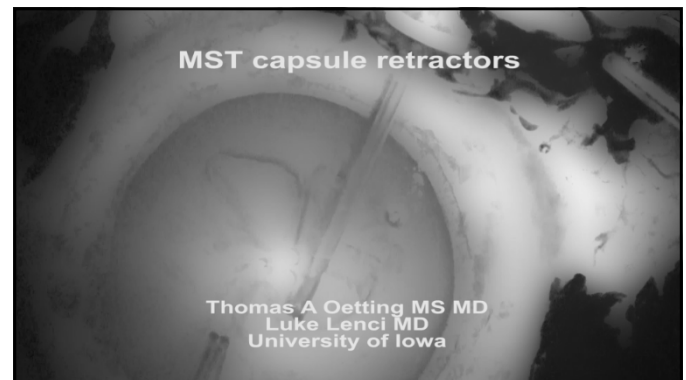
7



8



9



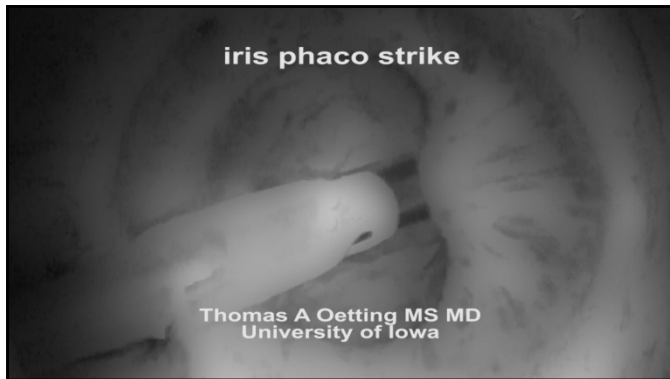10



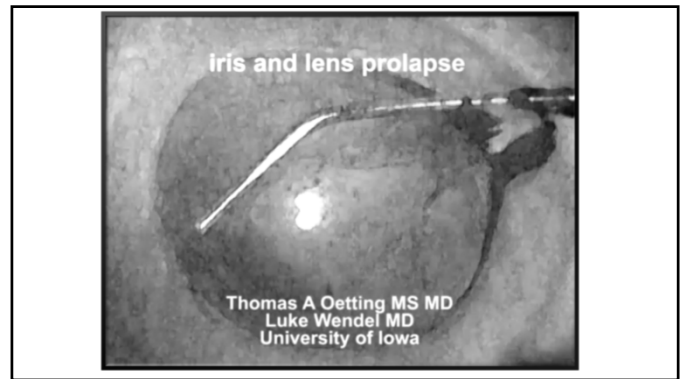
11



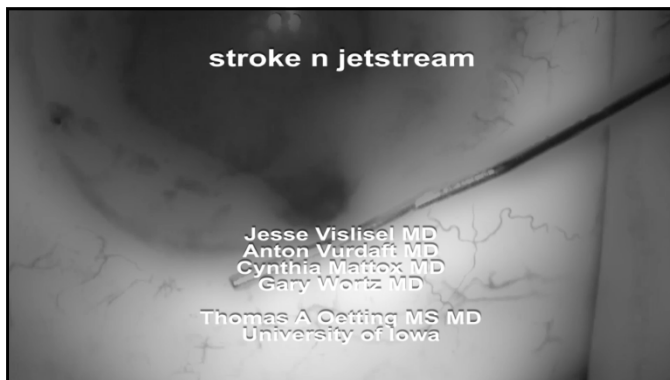
12



13



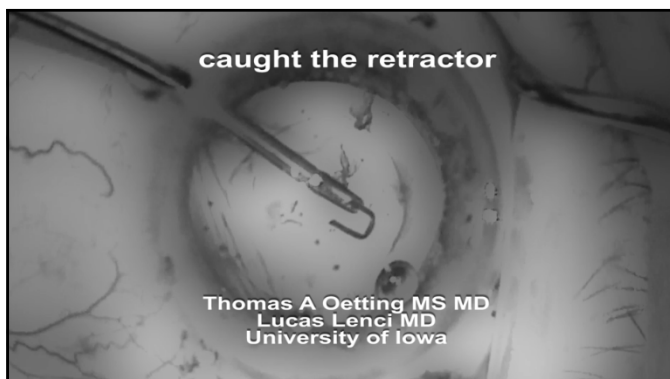
14



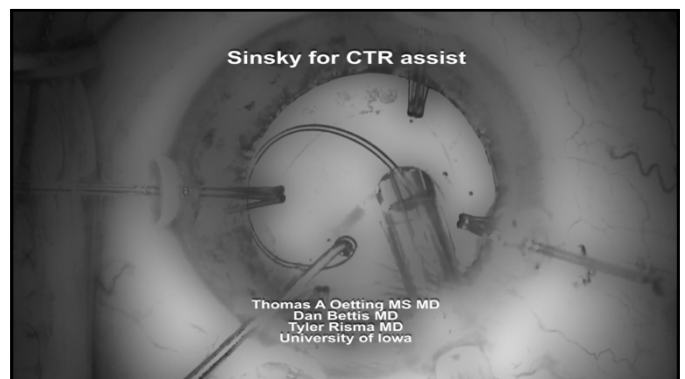
15



16



17



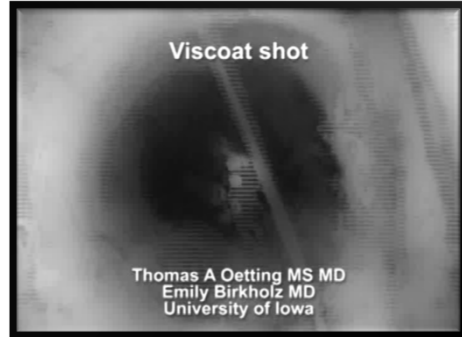18

5



19

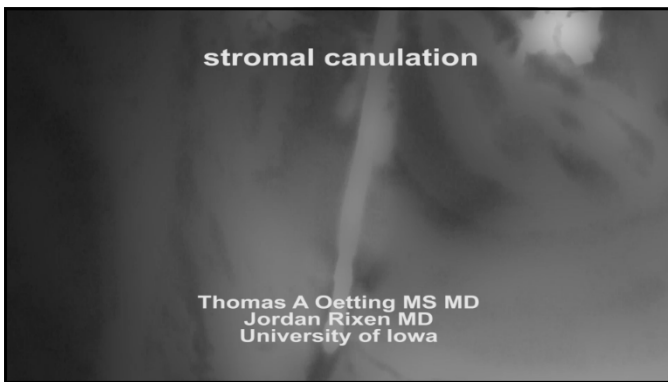
Viscoat shot



Thomas A Oetting MS MD
Emily Birkholz MD
University of Iowa

20


stromal canulation



Thomas A Oetting MS MD
Jordan Rixen MD
University of Iowa

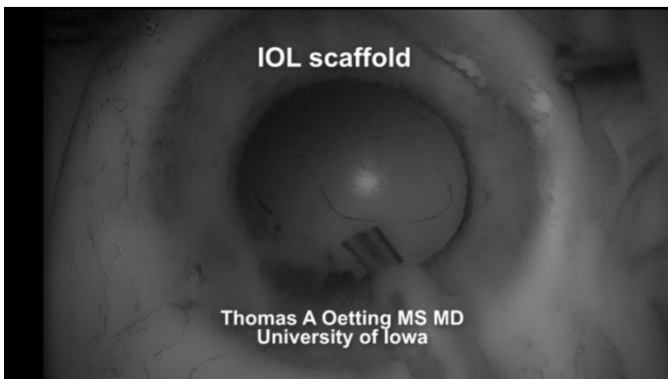
21

6



22

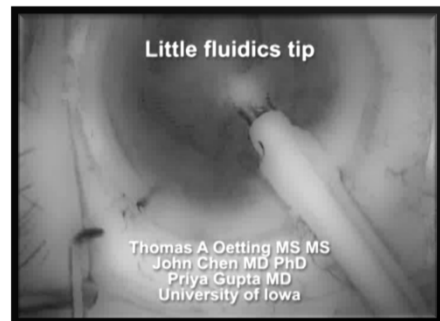
IOL scaffold



Thomas A Oetting MS MD
University of Iowa

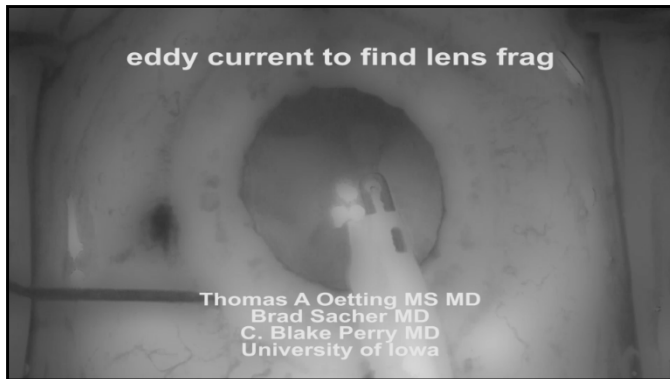23

Little fluidics tip

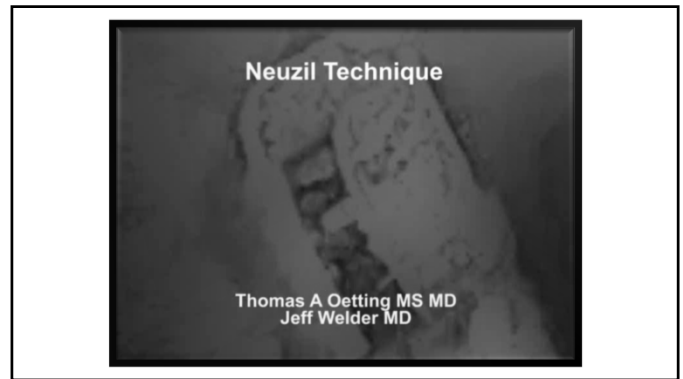

Thomas A Oetting MS MS
John Chen MD PhD
Priya Gupta MD
University of Iowa

24



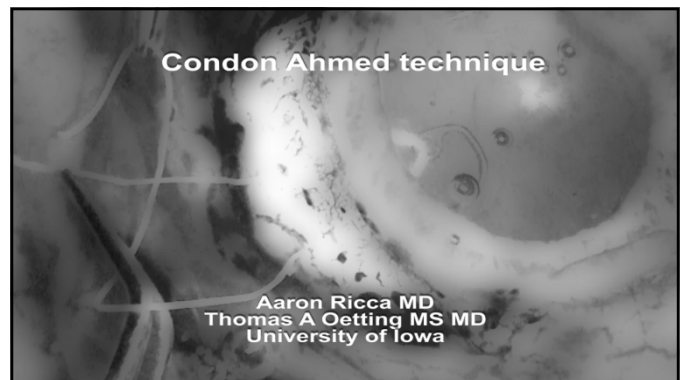25



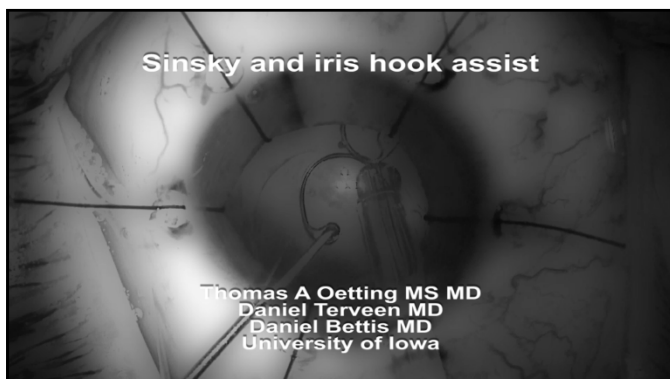
26



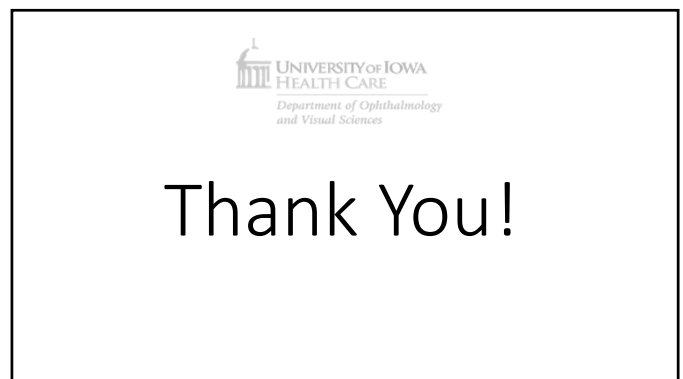27



28



29



30