

Dynamic cerebral reorganization in the pathophysiology of schizophrenia: a MRI-derived cortical thickness study

S. Guo^{1,2†}, L. Palaniyappan^{3,4,8*†}, P. F. Liddle³ and J. Feng^{2,5,6,7*}

¹Key Laboratory of High Performance Computing and Stochastic Information Processing (Ministry of Education of China), College of Mathematics and Computer Science, Hunan Normal University, Changsha, People's Republic of China

²Department of Computer Science, University of Warwick, Coventry, UK

³Division of Psychiatry & Applied Psychology, Centre for Translational Neuroimaging in Mental Health, Institute of Mental Health, University of Nottingham, Nottingham, UK

⁴Departments of Psychiatry, Medical Biophysics and Neuroscience, Schulich School of Medicine and Dentistry & Robarts Research Institute, Western University, London, Ontario, Canada

⁵Centre for Computational Systems Biology, College of Mathematical Sciences, Fudan University, Shanghai, People's Republic of China

⁶School of Life Sciences and Collaborative Innovation Center for Brain Science, Fudan University, Shanghai, People's Republic of China

⁷Shanghai Center for Mathematical Sciences, Shanghai, People's Republic of China

⁸Lawson Health Research Institute, London, Ontario, Canada

Background. A structural neuroanatomical change indicating a reduction in brain tissue is a notable feature of schizophrenia. Several pathophysiological processes such as aberrant cortical maturation, progressive tissue loss and compensatory tissue increase could contribute to the structural changes seen in schizophrenia.

Method. We studied cortical thickness using surface-based morphometry in 98 clinically stable patients with schizophrenia and 83 controls. Using a pattern classification approach, we studied whether the features that discriminate patients from controls vary across the different stages of the illness. Using a covariance analysis, we also investigated if concurrent *increases* accompany *decreases* in cortical thickness.

Results. Very high levels of accuracy (96.3%), specificity (98.8%) and sensitivity (88%) were noted when classifying patients with <2 years of illness from controls. Within the patient group, reduced thickness was consistently accompanied by increased thickness in distributed brain regions. A pattern of cortical amelioration or normalization (i.e. reduced deviation from controls) was noted with increasing illness duration. While temporo-limbic and fronto-parietal regions showed reduced thickness, the occipital cortex showed increased thickness, especially in those with a long-standing illness.

Conclusion. A compensatory remodelling process might contribute to the cortical thickness variations in different stages of schizophrenia. Subtle cerebral reorganization reflecting the inherent plasticity of brain may occur concomitantly with processes contributing to tissue reduction in adult patients with schizophrenia.

Received 23 July 2015; Revised 7 April 2016; Accepted 12 April 2016

Key words: Compensation, cortical thickness, covariance, pattern classification, schizophrenia, support vector machine.

Introduction

Robust changes in grey matter are observed using structural magnetic resonance imaging (MRI) in patients with schizophrenia both before and after the onset of psychosis, and are linked to the clinical features of the illness (Glahn *et al.* 2008; Bora *et al.* 2011; Chan *et al.* 2011). Rather controversially, these

neuroanatomical changes have been argued to be progressive in nature, indicating a deteriorating pathophysiological process (Weinberger & McClure, 2002; DeLisi, 2008; Hulshoff Pol & Kahn, 2008; Andreasen *et al.* 2011; Olabi *et al.* 2011; Vita *et al.* 2012). Longitudinal MRI studies report loss of grey matter at a rate that is often implausible (e.g. ~0.43% of frontal grey-matter volume/year in the first 12–15 years of illness; Andreasen *et al.* 2011) and if maintained, would result in little brain tissue being left after 2–3 decades of illness in an individual (Weinberger & McClure, 2002). In addition, the putative neuroprogressive changes do not seem to reflect the severity of clinical deterioration (McGlashan, 2006) even in the samples showing such significant tissue loss (Zipparo *et al.*

* Address for correspondence: Dr L. Palaniyappan MBBS, PhD, Robarts Research Institute, Western University, Room 3208, 100 Perth Drive, London, ON, N6A 5K8, Canada.

(Email: lpalaniy@uwo.ca) [L.P.]

(Email: jianfeng64@gmail.com) [J.F.]

† These authors contributed equally as joint first authors.

2008), although conflicting data exist in the literature (Van Haren *et al.* 2008; Andreasen *et al.* 2011). Some studies with notable sample sizes have failed to observe neuroprogressive changes (Schaufelberger *et al.* 2011), and instead report a significant increase in the volume of some brain regions (Roiz-Santiáñez *et al.* 2014). In light of this evidence, neuroprogression, if present, is likely to be limited not only in time (as highlighted by Van Haren *et al.* 2008) but also in spatial distribution (Rosa *et al.* 2015), and occur alongside compensatory changes in the opposite direction.

As pointed out recently (Zipursky *et al.* 2013), the idea of ‘neuroprogression’ or ‘structural degeneration’ is somewhat inconsistent with the improvement and/or stabilization in clinical and functional domains in a large number of patients (Arndt *et al.* 1995; Levine *et al.* 2011). Diffuse patterns of neuroanatomical changes reflect clinical features of schizophrenia, for example, grey-matter reduction in left-perisylvian regions is associated with positive symptoms, extended frontolimbic reductions with negative symptoms and temporal, insular and medial prefrontal changes with disorganization (Koutsouleris *et al.* 2008). Either a reversal of these changes, or the appearance of compensatory changes could be expected to occur in those with long-standing illness. McGlashan (2006) argued that the pathological brain changes in schizophrenia are a result of both destructive and ameliorative processes and suggested that chronic illness may lead to concomitant ‘disuse atrophy in some circuits and overuse hypertrophy in other circuits’. This prospect has not been examined in detail to date. Functional MRI studies note that increase in functional activation in certain regions compensates for the reduced activation of the primary task-relevant brain regions (Quintana *et al.* 2003; Tan *et al.* 2006), thus producing a rescuing effect in patients with a longer duration of illness (Faget-Agius *et al.* 2013). In terms of brain structure, if tissue reduction occurs as a primary change, then concomitant (covarying) increase in tissue in other brain regions can be expected to compensate for the deficits. Grey-matter increases are shown to be associated with clinical improvement in some patients with schizophrenia (Ansell *et al.* 2015), suggesting that such increases are likely to be ‘ameliorative’ or compensatory processes. But structural studies have mostly focused on localizing the regions with most consistent morphological change (Glahn *et al.* 2008; Bora *et al.* 2011; Chan *et al.* 2011), and have not paid close attention to the nature of relationship (covariance) among brain regions that can uncover the subtle changes in opposite direction that occur concomitantly.

Several distinct observations in a cross-sectional sample of patients with varying illness duration

could provide indirect evidence for ameliorative or compensatory neuroanatomical changes in schizophrenia. First, volumetric studies in schizophrenia suggest that while some brain regions with reduced grey matter in early stages show more pronounced deficits in chronic schizophrenia, several other regions with early reduction do not appear to have the same degree or more pronounced deficits in later stages (Ellison-Wright *et al.* 2008; Chan *et al.* 2011). This latter observation has not been adequately highlighted in the past but is readily evident in an extensive meta-analysis of stage-specific volumetric changes reported by Chan *et al.* (2011) (see Fig. 3 and Table 4). Thus, in the presence of an ameliorative process, brain regions showing pronounced changes in the early stages of illness will be expected to show less pronounced deviation from healthy controls in those with more chronic illness (hypothesis 1). Second, in the absence of a pathophysiological process affecting distributed brain regions (i.e. in healthy controls), widespread age-related decline occurs in cortical thickness, with few regional exceptions (e.g. primary visual cortex, medial temporal lobe) (Brans *et al.* 2010; Thambisetty *et al.* 2010; Storsve *et al.* 2014). Thus, within the population of healthy controls, the structural covariance between any two brain regions is more likely to show a positive than a negative relationship brought about by regionally non-specific determinants of tissue volume (i.e. both regions show concomitant increase or decrease in thickness across individuals). In contrast, provided active regional remodelling/compensation accompanies tissue reduction, a large number of negative covarying pairs of regions can be expected in patients (i.e. as one region shows thinning, another may show thickening across individuals) (hypothesis 2). Third, meta-analytical anatomical likelihood estimates of morphometric changes consistently demonstrate regions with relative tissue reduction but not tissue increase in different stages of schizophrenia (Chan *et al.* 2011; Fusar-Poli *et al.* 2011). This suggests that compensatory increases in grey matter, if present, are likely to be highly variable across individuals. As a result of the higher inter-individual variability of putative compensatory changes, we can expect a reduction in the discriminatory ability when using neuroanatomical patterns to differentiate controls from patients with longer illness duration (hypothesis 3).

We tested these hypotheses in a sample of 98 clinically stable patients receiving treatment for schizophrenia and 83 healthy controls using a pattern classification approach and covariance analysis of cortical thickness. We chose MRI-derived cortical thickness as several studies have previously established that altered cortical thickness is robust feature of schizophrenia (Kuperberg *et al.* 2003; Narr *et al.* 2005; Nesvåg *et al.*

2008; Venkatasubramanian *et al.* 2008; Schultz *et al.* 2010; Van Haren *et al.* 2011). Further thickness is more likely to reflect illness-related factors than surface area (Sprooten *et al.* 2013; Haukvik *et al.* 2014), making it a suitable index when studying the malleability of the cortex.

Method and materials

Participants

Ninety-eight patients at various stages of schizophrenia (80 males, 18 females) were recruited for this study. The mean illness duration assessed using case notes, patient interview and referral information as the time from the point of first contact with psychiatric services with psychotic symptoms to the date of scan acquisition for these patients was 5.5 years (median = 3 years, range 6 months–29 years). The diagnosis of schizophrenia (DSM-IV criteria) was made in accordance with the procedure of Leckman *et al.* (1982) using data from all available sources [case notes, a standardized clinical interview based on the Signs and Symptoms of Psychotic Illness scale (Liddle *et al.* 2002) and reports from other informants when required]. Subjects with neurological disorders, current substance dependence, IQ <70 using the Quick Test (Ammons & Ammons, 1962), and diagnosis of any other Axis I disorder were excluded. Seventy-eight out of 98 patients were receiving psychotropic medications (average dose in chlorpromazine equivalents 490 mg, range 25–3000 mg). Healthy controls were recruited from the local community via advertisements and comprised 83 subjects free of any psychiatric or neurological disorder matched groupwise in age (± 3 years) and socio-economic status (measured using National Statistics – Socio Economic Classification; Rose & Pevalin, 2003) to the patient group. Controls had similar exclusion criteria to patients; in addition subjects with history of psychotic illness in first-degree relatives were excluded. Regional Ethics Committees (Nottinghamshire and Derbyshire) approved the study and all participants provided written informed consent. More details are given in Table 1.

Image acquisition and morphometry

For details on image acquisition see Appendix 1 in the Supplementary material. Image processing for morphometry was carried out by a single researcher (L.P.) applying previously used criteria to reduce freesurfer-related processing artefacts (Appendix 1, Supplementary material) (Palaniyappan & Liddle, 2012). The cortical thickness was measured by calculating the Euclidean distance between linked vertices on the inner and outer cortical surfaces (Fischl & Dale,

2000), as shown in Fig. 1a, and in accordance with standard descriptions (Dale *et al.* 1999). Anatomical parcellations were obtained using the Destrieux sulcogyral atlas (Destrieux *et al.* 2010), which follows the anatomical conventions of Duvernoy (Duvernoy & Bourguoin, 1999). The details of the 148 resulting parcellations are presented in Supplementary Fig. S1 and Table S1. Regional thickness values were obtained from the mean thickness of all tessellations that were confined within the boundaries of the parcellated sulcogyral regions. Compared to the 148 values obtained per subject for regional thickness measures, vertexwise data provide more than 1 500 000 values per subject for pattern classification. Nevertheless, regional measures provide anatomically intuitive data that enables a meaningful interpretation of individual data points. Increasing the number of data dimensions in the presence of a limited sample size will affect the trade-off between complexity and error margin, resulting in overfitting (Song *et al.* 2011). Further, covariance between two anatomical regions is more readily interpretable than the covariance between two vertices in the cortical surface. For these reasons, we used parcellation-based regional thickness for pattern classification and covariance analysis as detailed below.

Pattern classification and covariance analysis

For pattern classification analysis, we used Support Vector Machine (SVM), a learning machine for two-class problems. SVM toolkit libsvm written by Lin Chih-Jen from Taiwan University (<http://www.csie.ntu.edu.tw/~cjlin/libsvm/>) was used with a radial basis function (RBF) as kernel function. In a different dataset published elsewhere (Guo *et al.* 2014) we tested optimal parameters for employing RBF-based SVM, and chose the values of $t=2$ and parameter $C=10$ to achieve a robust trade-off between model complexity and training error for our classification problem. Other SVM parameters were kept as default values, in line with our previous work (Guo *et al.* 2014). RBF has been shown to perform optimally when region-based neuroimaging data is used in SVM classification (Song *et al.* 2011). The trade-off parameter $C=10$ is the best one to get the highest accuracy rate between parameter range (1–15). To measure the test performance and to validate the classifier, a leave-one-subject-out cross-validation approach was employed, where the classifier is trained on all subjects except one, which is used as test data. Balanced accuracy, specificity, sensitivity, and predictive values for each classifier were obtained and statistical significance of these measures was determined by way of permutation testing ($n=1000$ permutations with random assignment of patient/control labels to the training data). Mean

Table 1. Demographic and clinical characteristics

	Schizophrenia patients ($n = 98$)	Healthy control ($n = 83$)	p value
Age (years)	30.3776 \pm 8.6781	29.4819 \pm 8.7239	0.4910 (t test)
Sex (M/F)	80/18	70/13	0.6303 (χ^2 test)
Intracranial volume	1371.2 \pm 238.02	1399.8 \pm 240.12	0.4233 (t test)
Illness duration (years)	5.5357 \pm 6.212	–	–
Chlorpromazine dose equivalents	389.9 \pm 501.7	–	–
SSPI score			
Psychomotor poverty	2.8673 \pm 3.1447	–	–
Reality distortion	2.4388 \pm 2.4371	–	–
Disorganization	0.9898 \pm 1.2141	–	–
Total score	10.898 \pm 6.8946	–	–

SSPI, Signs and symptoms in psychotic illness.

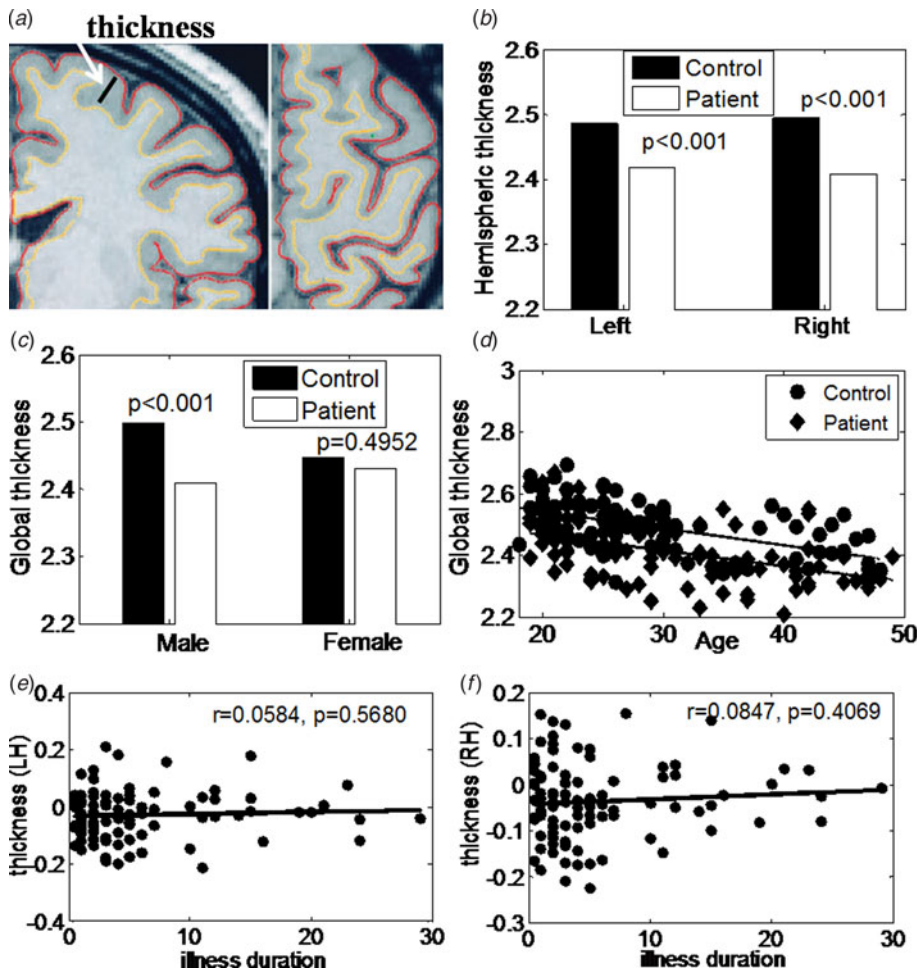


Fig. 1. (a) Coronal (left) and horizontal (right) slices of the left hemisphere with gray/white and pial surfaces overlaid. Thickness measures were obtained by calculating the shortest perpendicular distance between the two surfaces across the entire volume for global thickness but limited to boundaries of anatomical parcellations for regional thickness. (b) Comparison of mean hemispheric thickness between controls (black bar) and schizophrenia patients (white bar) of left and right hemisphere. There are significant differences between these two groups on both hemispheres. (c) Group difference between patients and controls in mean global thickness was seen in males but not in females. (d) Thickness has significant negative correlation with age both for controls and patients. (e) There was no significant relationship between residual of thickness after regressing out the influence of age and duration of illness in the patient group for both hemispheres.

discrimination accuracy, sensitivity and specificity was obtained for the entire sample. To study the effect of illness duration, we categorized patients into multiple bins on the basis of their illness duration as shown in Table 2 and Supplementary Table S6. The SVM classification was carried out for each bin independently, estimating the classification accuracy against the same set of controls using regional thickness measures after removing the linear effect of age and gender.

For covariance analysis structural cortical networks were constructed from the regional cortical thickness measurements of all 148 regions after removing the effects of age and gender, in line with previous studies (He *et al.* 2007; Zhang *et al.* 2012). More details of the mathematical computation are provided in the Supplementary material.

Demographic and clinical characteristics were compared using either two-sample t test or χ^2 test. Correlation analyses among normally distributed variables or residuals were conducted using Pearson's test.

Results

Global measures of thickness

Mean global thickness measures compared using two-sample t test revealed reduced thickness in patients compared to controls in both hemispheres (left: $p = 9.8 \times 10^{-7}$; right: $p = 6.9 \times 10^{-9}$), as shown in Fig. 1b. Group difference in mean global thickness was seen in males ($p < 0.001$) but not in females ($p = 0.50$), as shown in Fig. 1c. There was a significant negative relationship between age and global thickness in both groups (controls: $r = -0.55$, $p = 7.07 \times 10^{-8}$; schizophrenia: $r = -0.49$, $p = 3.7 \times 10^{-7}$), as shown in Fig. 1d. After regressing out the influence of age and gender, global thickness had no significant association with illness duration, although the correlation was numerically positive for both hemispheres (left: $r = 0.06$, $p = 0.57$; right: $r = 0.08$, $p = 0.41$), as shown in Fig. 1e. There was no significant difference of global thickness between two different scanners for all samples ($p = 0.7720$), for controls ($p = 0.3880$) and for patients ($p = 0.9566$) after controlling for duration, age and gender.

Regional measures of thickness

When all patients were compared to controls, 45 regions showed significantly reduced thickness (Bonferroni corrected). Most significant reduction was seen in parahippocampal gyrus ($p < 10^{-20}$ for left and right), supramarginal gyrus ($p < 10^{-20}$ for left and right), precentral gyrus ($p < 10^{-20}$ for left and right), temporal pole (left: $p < 10^{-20}$; right: $p = 10^{-16}$) and right superior insula ($p = 10^{-15}$). Eleven regions including inferior occipital gyrus (left: $p < 10^{-9}$; right: $p <$

10^{-11}), lateral fissures (left: $p < 10^{-9}$; right: $p < 10^{-8}$), occipital pole (left: $p < 10^{-8}$; right: $p < 10^{-8}$) and calcarine sulcus (left: $p < 10^{-6}$; right: $p < 10^{-9}$) showed significantly greater thickness in patients. The results are shown in Fig. 2.

Within the patient group, several regions showed significant correlation (uncorrected $p < 0.05$) with illness duration after regressing out the influence of age and gender (listed in Supplementary Table S2). Rather strikingly, the regions that showed significant reduction in thickness in the patients *v.* controls comparison, showed a positive association with illness duration, while those that had increased thickness showed a negative association. In other words, with increasing illness duration, the group differences in thickness had a tendency to 'normalize'.

To study if this 'normalization' across long illness duration occurs in regions that show notable differences in the early stage of illness (<2 years), we plotted the group difference of the mean residual of regional thickness for three regions with maximum group difference in the early stage (left and right parahippocampal, and left supramarginal gyrus), against the illness duration. As shown in Fig. 3a, a pattern of reducing deviation is seen with increasing illness duration across the group.

SVM classification

When the entire sample of patients and controls were compared on the basis of age- and gender-adjusted regional thickness, a discrimination accuracy of 81.77% with specificity 86.75% and sensitivity 77.55% was obtained. When patients were categorized to different illness duration bins, the discrimination accuracy reduced steadily when patients with longer durations were included in the classification matrix. We further studied this effect by studying four distinct subgroups of illness duration (<2, 2-4, 4-10, >10 years). Very high levels of accuracy (96.3%), specificity (98.8%) and sensitivity (88%) were noted for those with <2 years of illness. This was not affected by scanner or sample size differences (Supplementary Tables S7 and S8). The discrimination accuracy is shown in Table 2 and the best predictors in the different bins are shown in Supplementary Table S3.

Structural covariance

Pearson correlation matrices constructed for patients and controls are displayed in Fig. 3b. A large number of divergent relationships (negative covariance) were noted in patients compared to controls. When the strongest 100 relationships (irrespective of the spatial location) were considered in each group, 36 divergent (negative) relationships were seen in patients while

Table 2. Discrimination accuracy of thickness

Subgroups	Accuracy (%)	Specificity (%)	Sensitivity (%)
Cumulative duration bins			
All data (98 patients v. 83 controls)	81.77	86.75	77.55
<25 (97 patients v. 83 controls)	81.67	87.95	76.29
<20 (92 patients v. 83 controls)	85.71	95.18	77.17
<15 (87 patients v. 83 controls)	86.47	96.39	77.01
<10 (78 patients v. 83 controls)	87.58	96.39	78.21
<7 (74 patients v. 83 controls)	87.9	96.39	78.38
<6 (70 patients v. 83 controls)	89.54	97.59	80
<5 (61 patients v. 83 controls)	90.97	97.59	81.97
<4 (52 patients v. 83 controls)	92.59	98.8	84.62
<3 (42 patients v. 83 controls)	94.4	98.8	85.71
<2 (25 patients v. 83 controls)	96.3	98.8	88
Exclusive duration bins			
<2 (25 patients v. 83 controls)	96.3	98.8	88
2<D<4 (27 patients v. 83 controls)	92.73	100	70.37
4<D<10 (26 patients v. 83 controls)	88.07	100	50
D>10 (20 patients v. 83 controls)	80.58	100	0

D, Duration of illness.

Effects of covariates (age and gender) removed from this analysis using linear regression. See also Supplementary Tables S7 and S8.

only one relationship was divergent in controls, indicating that in patients, a number of regions increase in ('gain') thickness while some regions decrease ('loss'). The 36 regional pairs identified in this analysis are listed in Supplementary Table S4. When the within-group, inter-individual variation in the covariance scores were plotted for these 100 regional pairs, as shown in Fig. 3d, patients with schizophrenia had greater variances than controls (mean standard deviation in patients=2.1814, controls=1.0801; t test = -13.1107, $p < 0.001$), suggesting that the reciprocal (putatively compensatory) relationships do not always involve the same pairs of brain regions in patients. The correlation matrices were thresholded into a set of binarized matrices that describe the topological organization of the structural cortical networks for two groups. We examined different correlation thresholds (0–1 in steps of 0.05) to examine the proportion of divergent links (negative covariance) for all possible regional pairs at the different thresholds values. As shown in Fig. 3c, we noted that patients had more negative links for all thresholds, with the gap between the two groups widening notably when stronger pairwise relationships are considered. This pattern was not related to the dose of antipsychotics used by patients (Supplementary Fig. S3). These covariance results indicate that the patient group shows a larger than expected number of reciprocal changes in regional thickness.

A hub-and-spokes plot showing the covariance patterns for two brain regions with maximal group difference in each direction (left parahippocampal and supramarginal regions with reduced thickness and bilateral inferior occipital region with increased thickness in patients) is shown in Fig. 4. In these regions, patients had a number of divergent relationships with a distributed set of regions. More details are presented in Supplementary Table S5.

Discussion

In a large sample of patients recruited at a single centre (Nottingham), we investigated the effect of illness duration on cortical thickness and report four key observations. In accordance with our prediction, a pattern of concomitant group differences in both directions (i.e. relative increase and decrease) resulting in an overall reduction in anatomical deviation from controls was noted in later stages of schizophrenia. The ability to discriminate patients from controls on the basis of cortical thickness is greatest during the early phase of the illness, and reduces with longer illness duration. The features that discriminate a patient from controls vary across the different stages of the illness.

At the outset, it is important to note that our results neither imply an overall increase in thickness nor refute the appearance of more extensively distributed tissue reduction in later stages of schizophrenia. In fact,

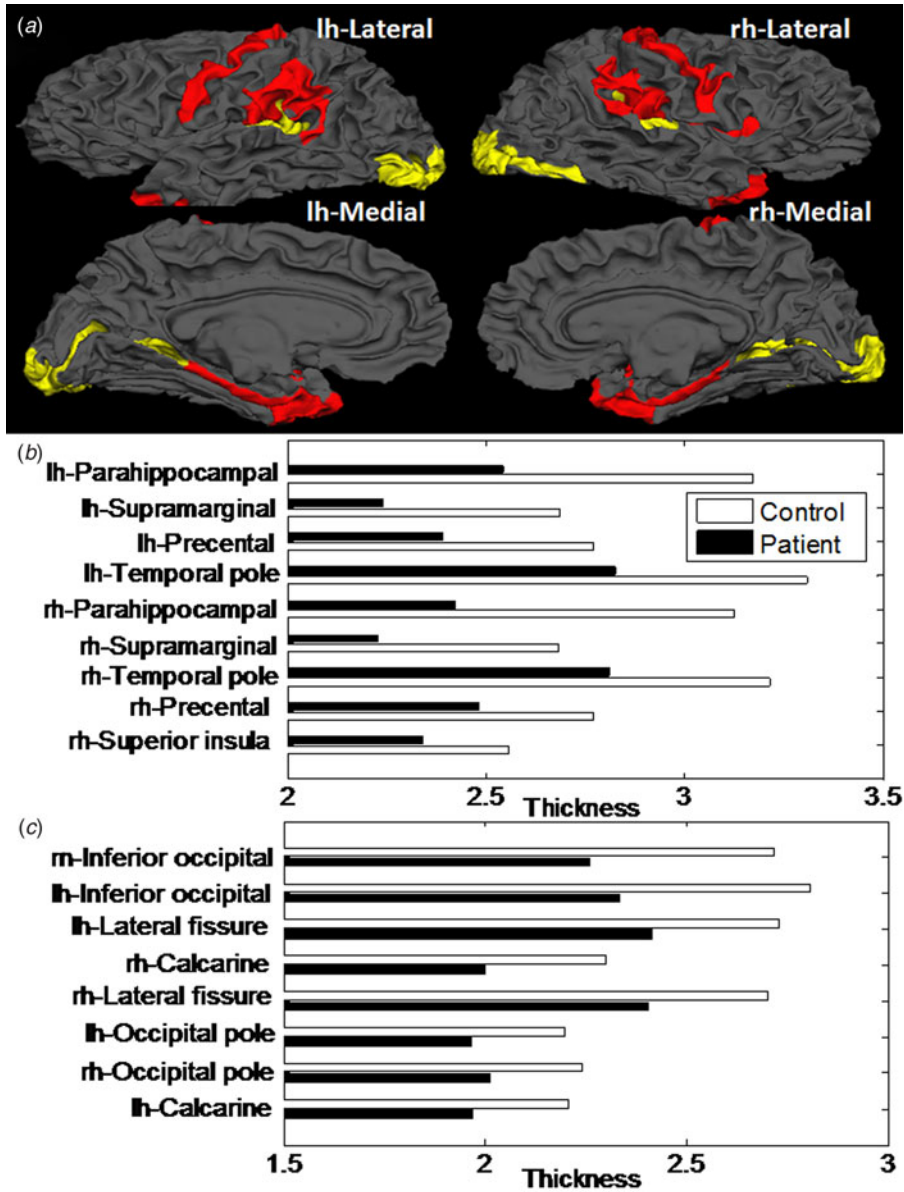


Fig. 2. Regions showing significant increase or decrease in thickness in patients compared to controls. (a) Regions in red show significant reduction in thickness in patients, while those in yellow show significant increase in thickness. Mean thickness values in each group for regions showing significant reduction in thickness in patients are shown in (b) and for regions with significant increase in thickness in patients displayed in (c).

the most prominent group difference in the entire sample, irrespective of illness duration, is a reduction in thickness seen in patients. We noted that in each duration bin, the best predictors in each classifier were regions showing reduced thickness in patients (Supplementary Table S3). This is consistent with meta-analyses of volumetric studies that show pronounced grey-matter reduction in the later stages of schizophrenia (Bora *et al.* 2011; Chan *et al.* 2011; Haijma *et al.* 2013). We add two important cross-sectional observations to this literature. (1) Across

subjects with schizophrenia, concomitant increases in thickness accompany reductions. (2) Regions showing most pronounced changes (increase or decrease) among patients in early stage of illness are not necessarily 'worse' among the patients in later stages of illness. Taken together, these observations are suggestive of a compensatory/remodelling process contributing to the cortical thickness variations in schizophrenia.

Using a structural covariance analysis we noted a higher number of reciprocal changes in thickness

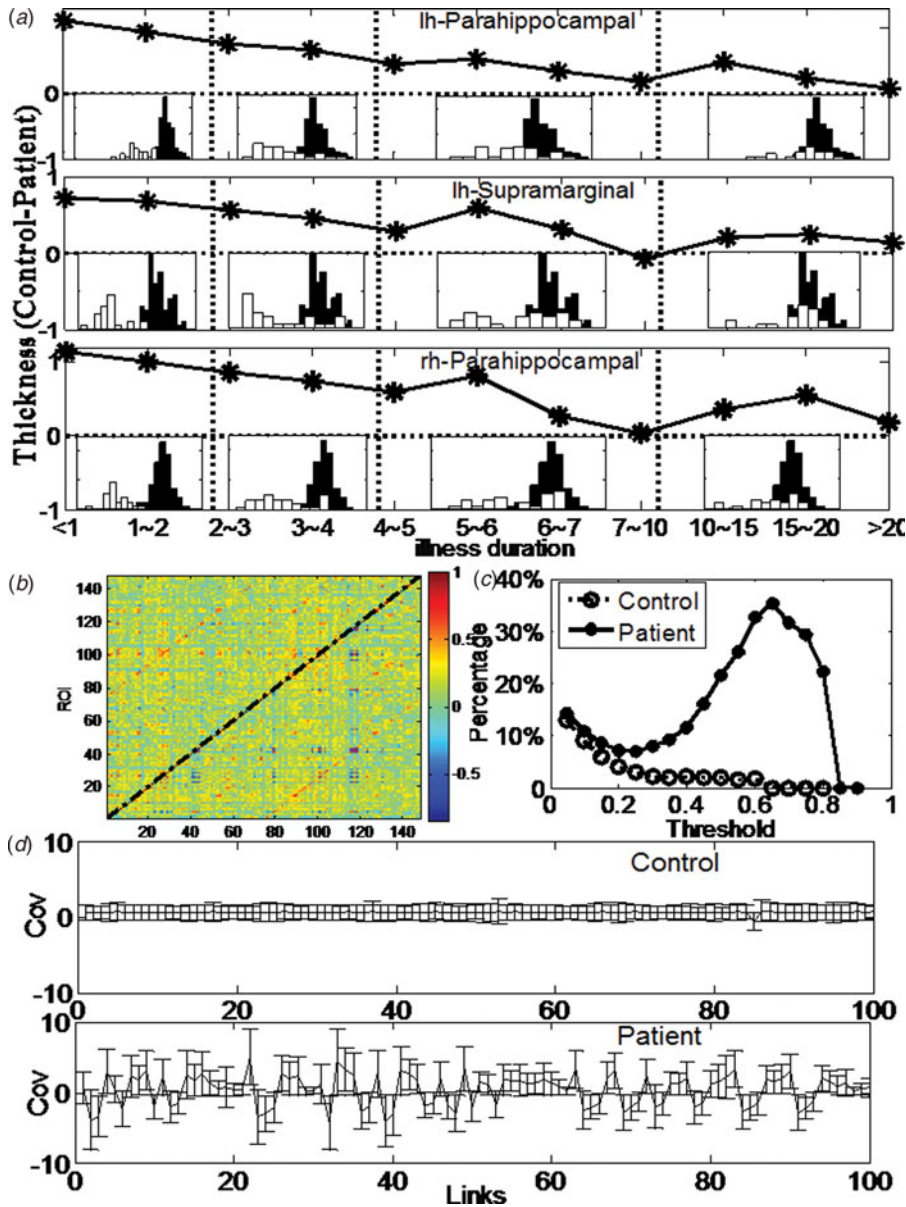


Fig. 3. (a) Traces of mean residual of thickness of top three regions of interest with significant difference between early stage (<2 years) illness and controls as a function of illness duration. The y axis represents the difference of the mean residual of regional thickness in controls compared to patients. The histogram in each time bin represents mean residual of regional thickness between patients with the corresponding illness *v.* all controls. (b) Correlation matrices constructed from thickness measure for two groups, where the lower triangular matrix represents the correlation coefficients of patients and the upper triangular matrix represents the correlation coefficients of controls. (c) The percentage of the divergent pairwise relationships for different correlation thresholds for all possible pairwise connections in the two groups. (d) The error bar of normalized covariant coefficients for the top 100 significant links in each group. The solid line represents mean normalized covariant coefficients of each link. Controls are in the upper row, patients in the lower row.

within the patient group than in controls. Most previous studies of cortical thickness in schizophrenia have sought the brain regions showing the largest magnitude of group differences, and predominantly report reduced thickness in patients (Kuperberg *et al.* 2003; Narr *et al.* 2005; Venkatasubramanian *et al.* 2008; Schultz *et al.* 2010). To the best of our knowledge

no study has investigated the concomitant changes in the brain that relate to localized changes in thickness. We note that regional thickness reduction is frequently accompanied by thickness increase in other brain regions in patients, with a high degree of between-subjects variation in the spatial distribution of the covariance patterns in patients. Further, the brain regions

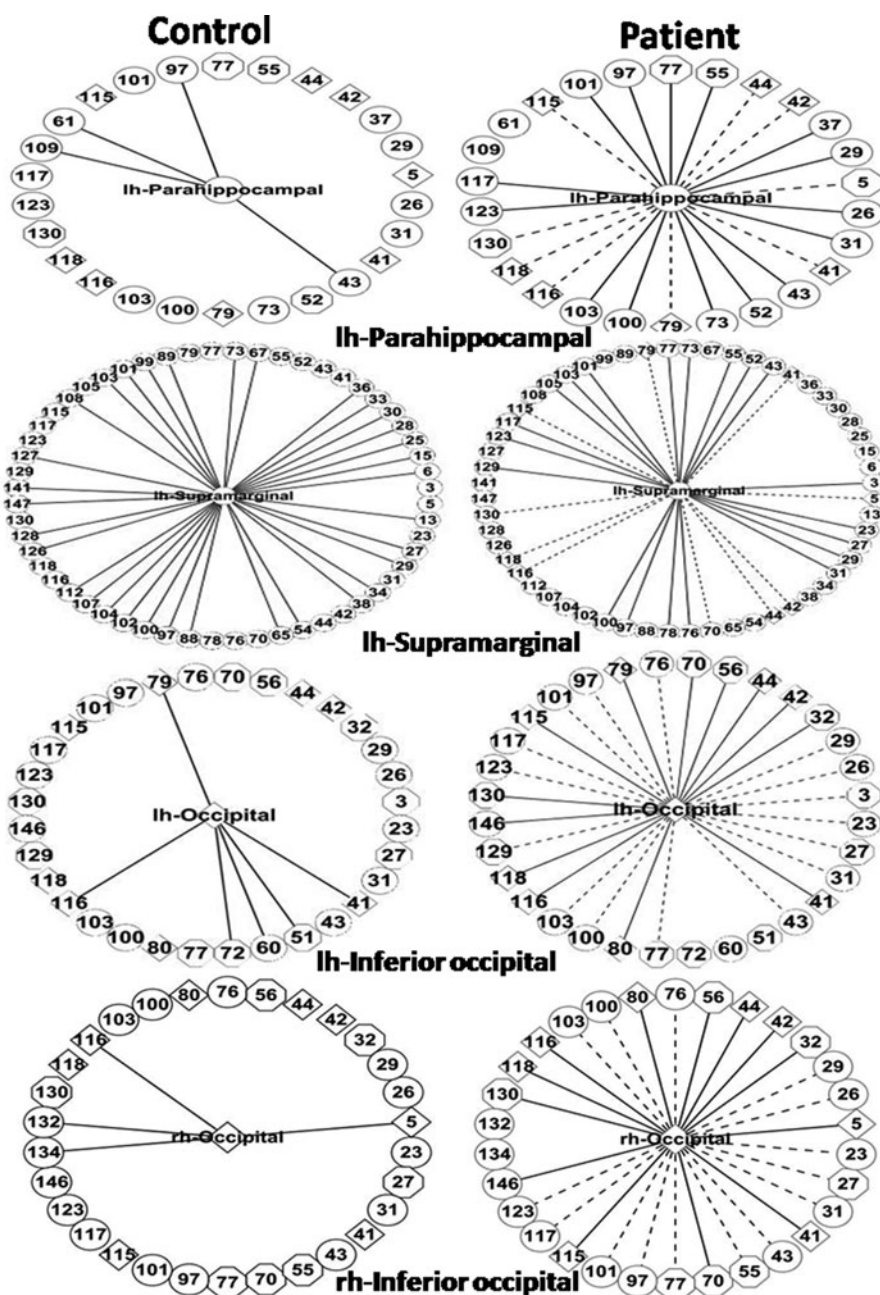


Fig. 4. Hub-and-spoke representation of the covariance between regions with significant group difference and rest of the brain. The central node represents the region with significant increase (occipital) or decrease (parahippocampal and supramarginal) in thickness. The outer nodes represent all brain regions that have a significant covariance with the central node either in the patient group or the control group. Regions with increased thickness (diamonds) and decreased thickness (circles) are separately identified from those that show no significant group differences in thickness (octagons). The spokes represent the relationship between the central and outer nodes. Long dash spokes represent negative (divergence of covariance) relationships while solid spokes represent positive (convergence of covariance) relationships. The numbers shown in the figure correspond to specific brain regions as listed in Supplementary Table S1. A colour version of this figure is provided as Supplementary Fig. S4.

with the most significant thickness reduction that best discriminate patients with <2 years of illness from controls, do not show the same magnitude of group difference in those with longer duration of illness. In line

with this obliteration, these regions do not retain their discriminatory ability when patients with longer duration of illness are compared with controls. Due to the cross-sectional nature of our sample, we cannot

infer whether this obliteration is taking place in the same set of individuals over the illness course. But these observations lead us to speculate that a secondary remodelling process that influences brain structure may be present in schizophrenia. In a large sample of patients with differing illness duration (range 6 months–29 years) followed up for 5 years, the rate of change of cortical thickness (reduction) was notably pronounced in patients, irrespective of their age (Van Haren *et al.* 2011). This higher rate of thinning over the course of 5 years indicates a dynamic morphometric process, but not necessarily ‘degeneration’ or a progressive deviation from normality. Interestingly, in line with our results, in that study several regions that showed higher baseline thickness revealed increased thinning over the course of illness, resulting in ‘normalization’ though this was not explicitly examined (Van Haren *et al.* 2011). Taken together, these observations contradict a ubiquitous degenerative process, and highlight the dynamic/plastic nature of the morphological changes that index a reorganization process whereby during the course of illness, the difference between patients and controls may become less pronounced.

In our sample, the most significant group differences in thickness involved the bilateral parahippocampal, supramarginal and temporal pole regions, and the precentral and superior anterior insula regions, while increase in thickness was mostly limited to regions in the occipital cortex. Thinning of parahippocampal region is also a well-documented feature of schizophrenia (Kuperberg *et al.* 2003; Van Haren *et al.* 2011). Parahippocampal thinning may be related to the risk of psychosis, with many studies reporting parahippocampal thinning/volume reduction in ultra-high-risk subjects (Jung *et al.* 2011; Mechelli *et al.* 2011; Tognin *et al.* 2014) and in those with the genetic risk (Goghari *et al.* 2007; Palaniyappan *et al.* 2012). Both occipital thickening (Szeszko *et al.* 2012; Yoon *et al.* 2007; Mané *et al.* 2009; Van Haren *et al.* 2011; Xiao *et al.* 2015) and lack of thinning (Nesvåg *et al.* 2008) in schizophrenia has been noted in previous studies. In particular (Szeszko *et al.* 2012) found that patients responding to antipsychotic treatment have a higher occipital thickness than non-responders, suggesting that the occipital thickening is of prognostic importance. In line with this, Mitelman & Buchsbaum (2007) suggested that the loss of grey matter in the posterior aspect of the brain (including occipital cortex) is a feature of poor outcome in schizophrenia. Occipital thickening appears to arise early and is seen in conjunction with thinning in patients with untreated first episode schizophrenia (Xiao *et al.* 2015). While the plasticity of multimodal, representational cortex may be reduced in schizophrenia (Fisher *et al.* 2013) the

increase in grey matter restricted to the visual cortex suggest that putative compensatory responses in schizophrenia may be more localized to the primary sensory cortices than in other regions.

We achieved a very high degree of accuracy (96.3% for the first 2 years) when discriminating patients from controls, after removing effect of age and gender. This high accuracy deteriorated steadily when all patients irrespective of their stage of illness were included in the discrimination model. We consider this finding as important in the context of increasing relevance of machine learning approaches in diagnosis and outcome prediction in schizophrenia (Lawrie *et al.* 2011; Borgwardt & Fusar-Poli, 2012; Koutsouleris *et al.* 2014). A number of studies, using varied neuroimaging features, report an accuracy ranging between 65% and 90% in discriminating patients from controls (Orrù *et al.* 2012; Veronese *et al.* 2013; Zarogianni *et al.* 2013). Models that provide >90% accuracy can substantially reduce the proportion of uncertainty inherent to classification (Kasperek *et al.* 2011; Iwabuchi *et al.* 2013). For the first time, we have examined the effect of illness duration on the utility of machine learning in schizophrenia, and note that the features that differentiate patients from controls are likely to be specific to the stage of illness. A classifier to separate a patient with schizophrenia from healthy control is redundant for clinical use even if is >90% accurate, as such an accurate separation can be readily made by clinicians. But it is worth noting that a great deal of investment is being made on prognostic prediction using neuroanatomical features. Our results suggest that acknowledging the process of obliteration of pathophysiological changes and incorporating stage-specific predictors could improve the sensitivity of classification approaches across various imaging modalities, and move us closer to the goal of using neuroanatomical features for prospective patient selection in future clinical trials in schizophrenia.

In clinical samples, patients in early stage of illness are likely to have varied outcome trajectories and thus more diverse pathophysiological signatures compared to patients with more established chronic illness. With chronicity the degree of clinical heterogeneity reduces to some extent as only those who require continued support remain with services. Despite this, we note that the neuroanatomical features in chronic sample are less informative than the pattern seen in earlier stages, suggesting that the degree of putative anatomical reorganization in more representative samples may indeed be greater than that captured by this study.

Our study has several strengths. The sample was recruited from a single site, with identical acquisition parameters used in the two scanners and identical

image processing. Further, we demonstrate (Supplementary Table S7) that the scanner variation does not influence the observed results. We studied the entire cortical surface without restricting our analysis to *a priori* regions. Studies estimating lobar volumes are likely to miss the reciprocal regional changes; in contrast, we examined anatomically defined sulcogyral subdivisions to capture thickness changes in both directions.

The limitations of the present study include the lack of longitudinal data to estimate illness onset, exposure to recreational substances and antipsychotic medications in a systematic manner. Structural changes are suspected to be linked to exposure to antipsychotics (Ho *et al.* 2011). We did not have the data for cumulative antipsychotic exposure for this sample. Nevertheless, when the effect due to the prescribed antipsychotic dose in our sample of clinically stable patients (dose unchanged at least for a period of 6 weeks at the time of scan) was removed from the analysis, the results were not altered (Supplementary Fig. S3). We cannot conclude whether the putative ameliorative changes reported here depend on exposure to antipsychotics. Longitudinal follow-up, ideally starting during the prodrome, is the best design to address the question of compensatory brain changes; cross-sectional data such as the one presented here are likely to be affected by a confound between generational or cohort differences and age. We controlled for age in our analyses, but acknowledge that this may not be sufficient to eliminate the cohort effects in a cross-sectional design. To date, most longitudinal structural studies have had a modest range of follow-up periods (median time of 2.4 years), and rarely capture the brain changes right from the onset or beyond 7 years of illness (Vita *et al.* 2012). In addition, multiple changes in image acquisition procedures that often take place during longitudinal studies greatly affect the ability to observe spatially circumscribed changes (as opposed to total brain volume or lobar volume) in a reliable manner (Takao *et al.* 2013). The neurohistological basis of changes in MRI-derived cortical thickness is unclear, although this measure corresponds closely to biopsy-based measurement of cortical thickness (Cardinale *et al.* 2014). Nevertheless, in the wake of the limitations discussed here, our results regarding putative 'normalization' at later stages of schizophrenia must be considered preliminary until examined in a follow-up design.

Neuroimaging-based machine-learning approaches are considered as promising tools for a stratified approach in psychiatry (Lawrie *et al.* 2011; Borgwardt & Fusar-Poli, 2012; Koutsouleris *et al.* 2014). Considering the neuroanatomy of schizophrenia as a dynamic reorganization rather than static alteration will greatly improve the accuracy of diagnostic/outcome prediction

and the clinical utility of MRI scans. Our observations also raise the possibility that if the compensatory brain changes can be further characterized in schizophrenia, harnessing brain's plasticity optimally for therapeutic purposes may become feasible in the near future.

Supplementary material

For supplementary material accompanying this paper visit <http://dx.doi.org/10.1017/S0033291716000994>.

Acknowledgements

We are grateful for the assistance of Dr Pavan Mallikarjun, Dr Vijender Balain and other colleagues of Centre for Translational Neuroimaging in Mental Health for helping with recruitment and clinical data acquisition. Professor Dorothee Auer (Division of Radiological Sciences, University of Nottingham) and Professor Penny Gowland (Sir Peter Mansfield MR Centre) advised on image acquisition. We also extend our gratitude to all the patients who took part in the study.

L.P. was originally supported by a Grant from the Wellcome Trust (grant no. 076448/Z/05/Z) and currently by the Department of Psychiatry & Schulich School of Medicine Dean's Support funds, Western University, Ontario. Data acquisition for this study was in part supported by Medical Research Council Grant: G0601442. J.F.F. is a Royal Society Wolfson Research Merit Award holder. J.F.F. is also partially supported by the National High Technology Research and Development Program of China (No. 2015AA 020507) and the key project of Shanghai Science & Technology Innovation Plan (No. 15JC1400101). The research was partially supported by the National Centre for Mathematics and Interdisciplinary Sciences (NCMIS) of the Chinese Academy of Sciences and Key Program of National Natural Science Foundation of China (No. 91230201). S.G. is supported by the National Natural Science Foundation of China (NSFC) (grant no. 11271121), the Program for New Century Excellent Talents in University (NCET-13-0786) and the Natural Science Foundation of Hunan Province (2015JJ1010).

Declaration of Interest

All authors report no biomedical financial interests or potential conflicts of interest.

References

Ammons RB, Ammons CH (1962). The quick test (QT): provisional manual. *Psychological Reports* **11**, 111–161.

- Andreasen NC, Nopoulos P, Magnotta V, Pierson R, Ziebell S, Ho B-C** (2011). Progressive brain change in schizophrenia: a prospective longitudinal study of first-episode schizophrenia. *Biological Psychiatry* **70**, 672–679.
- Ansell BRE, Dwyer DB, Wood SJ, Bora E, Brewer WJ, Proffitt TM, Velakoulis D, McGorry PD, Pantelis C** (2015). Divergent effects of first-generation and second-generation antipsychotics on cortical thickness in first-episode psychosis. *Psychological Medicine* **45**, 515–527.
- Arndt S, Andreasen NC, Flaum M, Miller D, Nopoulos P** (1995). A longitudinal study of symptom dimensions in schizophrenia. Prediction and patterns of change. *Archives of General Psychiatry* **52**, 352–360.
- Bora E, Fornito A, Radua J, Walterfang M, Seal M, Wood SJ, Yücel M, Velakoulis D, Pantelis C** (2011). Neuroanatomical abnormalities in schizophrenia: a multimodal voxelwise meta-analysis and meta-regression analysis. *Schizophrenia Research* **127**, 46–57.
- Borgwardt S, Fusar-Poli P** (2012). Third-generation neuroimaging in early schizophrenia: translating research evidence into clinical utility. *British Journal of Psychiatry* **200**, 270–272.
- Brans RGH, Kahn RS, Schnack HG, Baal GCM, Van Posthuma D, Haren NEM, van Lepage C, Lerch JP, Collins DL, Evans AC, Boomsma DI, Pol HEH** (2010). Brain plasticity and intellectual ability are influenced by shared genes. *Journal of Neuroscience* **30**, 5519–5524.
- Cardinale F, Chinnici G, Bramerio M, Mai R, Sartori I, Cossu M, Lo Russo G, Castana L, Colombo N, Caborni C, De Momi E, Ferrigno G** (2014). Validation of FreeSurfer-estimated brain cortical thickness: comparison with histologic measurements. *Neuroinformatics* **12**, 535–542.
- Chan RCK, Di X, McAlonan GM, Gong Q** (2011). Brain anatomical abnormalities in high-risk individuals, first-episode, and chronic schizophrenia: an activation likelihood estimation meta-analysis of illness progression. *Schizophrenia Bulletin* **37**, 177–188.
- Dale AM, Fischl B, Sereno MI** (1999). Cortical surface-based analysis: I. segmentation and surface reconstruction. *NeuroImage* **9**, 179–194.
- DeLisi LE** (2008). The concept of progressive brain change in schizophrenia: implications for understanding schizophrenia. *Schizophrenia Bulletin* **34**, 312–321.
- Destrieux C, Fischl B, Dale A, Halgren E** (2010). Automatic parcellation of human cortical gyri and sulci using standard anatomical nomenclature. *NeuroImage* **53**, 1–15.
- Duvernoy HM, Bourgouin P** (1999). *The Human Brain: Surface, Three-Dimensional Sectional Anatomy with MRI, and Blood Supply*. Springer-Verlag/Wien.
- Ellison-Wright I, Glahn DC, Laird AR, Thelen SM, Bullmore E** (2008). The anatomy of first-episode and chronic schizophrenia: an anatomical likelihood estimation meta-analysis. *American Journal of Psychiatry* **165**, 1015–1023.
- Faget-Agius C, Boyer L, Lançon C, Richieri R, Fassio E, Soulier E, Chanoine V, Auquier P, Ranjeva JP, Guye M** (2013). Structural and functional reorganization of working memory system during the first decade in schizophrenia. A cross-sectional study. *Schizophrenia Research* **151**, 48–60.
- Fischl B, Dale AM** (2000). Measuring the thickness of the human cerebral cortex from magnetic resonance images. *Proceedings of the National Academy of Sciences USA* **97**, 11050–11055.
- Fisher M, Loewy R, Hardy K, Schlosser D, Vinogradov S** (2013). Cognitive interventions targeting brain plasticity in the prodromal and early phases of schizophrenia. *Annual Review of Clinical Psychology* **9**, 435–463.
- Fusar-Poli P, Radua J, McGuire P, Stefan B** (2011). Neuroanatomical maps of psychosis onset: voxel-wise meta-analysis of antipsychotic-naïve VBM studies. *Schizophrenia Bulletin* **38**, 1297–1307.
- Glahn DC, Laird AR, Ellison-Wright I, Thelen SM, Robinson JL, Lancaster JL, Bullmore E, Fox PT** (2008). Meta-analysis of gray matter anomalies in schizophrenia: application of anatomic likelihood estimation and network analysis. *Biological Psychiatry* **64**, 774–781.
- Goghari VM, Rehm K, Carter CS, MacDonald AW** (2007). Regionally specific cortical thinning and gray matter abnormalities in the healthy relatives of schizophrenia patients. *Cerebral Cortex* **17**, 415–424.
- Guo S, Palaniyappan L, Yang B, Liu Z, Xue Z, Feng J** (2014). Anatomical distance affects functional connectivity in patients with schizophrenia and their siblings. *Schizophrenia Bulletin* **40**, 449–459.
- Haijma SV, Haren NV, Cahn W, Koolschijn PCMP, Pol HEH, Kahn RS** (2013). Brain volumes in schizophrenia: a meta-analysis in over 18 000 Subjects. *Schizophrenia Bulletin* **39**, 1129–1138.
- Haukvik UK, Rimol LM, Roddey JC, Hartberg CB, Lange EH, Vaskinn A, Melle I, Andreassen OA, Dale A, Agartz I** (2014). Normal birth weight variation is related to cortical morphology across the psychosis spectrum. *Schizophrenia Bulletin* **40**, 410–419.
- He Y, Chen ZJ, Evans AC** (2007). Small-world anatomical networks in the human brain revealed by cortical thickness from MRI. *Cerebral Cortex* **17**, 2407–2419.
- Ho B-C, Andreasen NC, Ziebell S, Pierson R, Magnotta V** (2011). Long-term antipsychotic treatment and brain volumes: a longitudinal study of first-episode schizophrenia. *Archives of General Psychiatry* **68**, 128–137.
- Hulshoff Pol HE, Kahn RS** (2008). What happens after the first episode? A review of progressive brain changes in chronically ill patients with schizophrenia. *Schizophrenia Bulletin* **34**, 354–366.
- Iwabuchi S, Liddle PF, Palaniyappan L** (2013). Clinical utility of machine learning approaches in schizophrenia: improving diagnostic confidence for translational neuroimaging. *Frontiers in Neuropsychiatric Imaging and Stimulation* **4**, 95.
- Jung WH, Kim JS, Jang JH, Choi J-S, Jung MH, Park J-Y, Han JY, Choi C-H, Kang D-H, Chung CK, Kwon JS** (2011). Cortical thickness reduction in individuals at ultra-high-risk for psychosis. *Schizophrenia Bulletin* **37**, 839–849.
- Kasperek T, Thomaz CE, Sato JR, Schwarz D, Janousova E, Marecek R, Prikryl R, Vanicek J, Fujita A, Ceskova E** (2011). Maximum-uncertainty linear discrimination analysis of first-episode schizophrenia subjects. *Psychiatry Research: Neuroimaging* **191**, 174–181.

- Koutsouleris N, Davatzikos C, Borgwardt S, Gaser C, Bottlender R, Frodl T, Falkai P, Riecher-Rössler A, Möller H-J, Reiser M, Pantelis C, Meisenzahl E (2014). Accelerated brain aging in schizophrenia and beyond: a neuroanatomical marker of psychiatric disorders. *Schizophrenia Bulletin* **40**, 1140–1153.
- Koutsouleris N, Gaser C, Jäger M, Bottlender R, Frodl T, Holzinger S, Schmitt GJE, Zetsche T, Burgermeister B, Scheuerecker J, Born C, Reiser M, Möller H-J, Meisenzahl EM (2008). Structural correlates of psychopathological symptom dimensions in schizophrenia: a voxel-based morphometric study. *NeuroImage* **39**, 1600–1612.
- Kuperberg GR, Broome MR, McGuire PK, David AS, Eddy M, Ozawa F, Goff D, West WC, Williams SCR, Van der Kouwe AJW, Salat DH, Dale AM, Fischl B (2003). Regionally localized thinning of the cerebral cortex in schizophrenia. *Archives of General Psychiatry* **60**, 878–888.
- Lawrie SM, Olabi B, Hall J, McIntosh AM, Sm L, BO JH, Am M (2011). Do we have any solid evidence of clinical utility about the pathophysiology of schizophrenia? *World Psychiatry* **10**, 19.
- Leckman JF, Sholomskas D, Thompson D, Belanger A, Weissman MM (1982). Best estimate of lifetime psychiatric diagnosis: a methodological study. *Archives of General Psychiatry* **39**, 879–883.
- Levine SZ, Lurie I, Kohn R, Levav I (2011). Trajectories of the course of schizophrenia: from progressive deterioration to amelioration over three decades. *Schizophrenia Research* **126**, 184–191.
- Liddle PF, Ngan ETC, Duffield G, Kho K, Warren AJ (2002). Signs and symptoms of psychotic illness (SSPI): a rating scale. *British Journal of Psychiatry* **180**, 45–50.
- Mané A, Falcon C, Mateos JJ, Fernandez-Egea E, Horga G, Lomeña F, Bargalló N, Prats-Galino A, Bernardo M, Parellada E (2009). Progressive gray matter changes in first episode schizophrenia: a 4-year longitudinal magnetic resonance study using VBM. *Schizophrenia Research* **114**, 136–143.
- McGlashan TH (2006). Is active psychosis neurotoxic? *Schizophrenia Bulletin* **32**, 609–613.
- Mechelli A, Riecher-Rössler A, Meisenzahl EM, Tognin S, Wood SJ, Borgwardt SJ, Koutsouleris N, Yung AR, Stone JM, Phillips LJ, McGorry PD, Valli I, Velakoulis D, Woolley J, Pantelis C, McGuire P (2011). Neuroanatomical abnormalities that predate the onset of psychosis: a multicenter study. *Archives of General Psychiatry* **68**, 489–495.
- Mitelman SA, Buchsbaum MS (2007). Very poor outcome schizophrenia: clinical and neuroimaging aspects. *International Review of Psychiatry (Abingdon, England)* **19**, 345–357.
- Narr KL, Bilder RM, Toga AW, Woods RP, Rex DE, Szeszko PR, Robinson D, Sevy S, Gunduz-Bruce H, Wang Y-P, DeLuca H, Thompson PM (2005). Mapping cortical thickness and gray matter concentration in first episode schizophrenia. *Cerebral Cortex* **15**, 708–719.
- Nesvåg R, Lawyer G, Varnäs K, Fjell AM, Walhovd KB, Frigessi A, Jönsson EG, Agartz I (2008). Regional thinning of the cerebral cortex in schizophrenia: effects of diagnosis, age and antipsychotic medication. *Schizophrenia Research* **98**, 16–28.
- Olabi B, Ellison-Wright I, McIntosh AM, Wood SJ, Bullmore E, Lawrie SM (2011). Are there progressive brain changes in schizophrenia? A meta-analysis of structural magnetic resonance imaging studies. *Biological Psychiatry* **70**, 88–96.
- Orrù G, Pettersson-Yeo W, Marquand AF, Sartori G, Mechelli A (2012). Using support vector machine to identify imaging biomarkers of neurological and psychiatric disease: a critical review. *Neuroscience & Biobehavioral Reviews* **36**, 1140–1152.
- Palaniyappan L, Balain V, Liddle PF (2012). The neuroanatomy of psychotic diathesis: a meta-analytic review. *Journal of Psychiatric Research* **46**, 1249–1256.
- Palaniyappan L, Liddle PF (2012). Aberrant cortical gyrification in schizophrenia: a surface-based morphometry study. *Journal of Psychiatry & Neuroscience* **37**, 110119.
- Quintana J, Wong T, Ortiz-Portillo E, Kovalik E, Davidson T, Marder SR, Mazziotta JC (2003). Prefrontal-posterior parietal networks in schizophrenia: primary dysfunctions and secondary compensations. *Biological Psychiatry* **53**, 12–24.
- Roiz-Santiañez R, Ayesa-Arriola R, Tordesillas-Gutiérrez D, Ortiz-García de la Foz V, Pérez-Iglesias R, Pazos A, Sánchez E, Crespo-Facorro B (2014). Three-year longitudinal population-based volumetric MRI study in first-episode schizophrenia spectrum patients. *Psychological Medicine* **44**, 1591–1604.
- Rosa PGP, Zanetti MV, Duran FLS, Santos LC, Menezes PR, Sczufca M, Murray RM, Busatto GF, Schaufelberger MS (2015). What determines continuing grey matter changes in first-episode schizophrenia and affective psychosis? *Psychological Medicine* **45**, 817–828.
- Rose D, Pevalin DJ (2003). *A Researcher's Guide to the National Statistics Socio-economic Classification*. Sage Publications: London.
- Schaufelberger MS, Lappin JM, Duran FLS, Rosa PGP, Uchida RR, Santos LC, Murray RM, McGuire PK, Sczufca M, Menezes PR, Busatto GF (2011). Lack of progression of brain abnormalities in first-episode psychosis: a longitudinal magnetic resonance imaging study. *Psychological Medicine* **41**, 1677–1689.
- Schultz CC, Koch K, Wagner G, Roebel M, Schachtzabel C, Gaser C, Nenadic I, Reichenbach JR, Sauer H, Schlösser RGM (2010). Reduced cortical thickness in first episode schizophrenia. *Schizophrenia Research* **116**, 204–209.
- Song S, Zhan Z, Long Z, Zhang J, Yao L (2011). Comparative study of SVM methods combined with voxel selection for object category classification on fMRI data. *PLoS ONE* **6**, e17191.
- Sprooten E, Pappmeyer M, Smyth AM, Vincenz D, Honold S, Conlon GA, Moorhead TWJ, Job D, Whalley HC, Hall J, McIntosh AM, Owens DCG, Johnstone EC, Lawrie SM (2013). Cortical thickness in first-episode schizophrenia patients and individuals at high familial risk: a cross-sectional comparison. *Schizophrenia Research* **151**, 259–264.
- Storsve AB, Fjell AM, Tamnes CK, Westlye LT, Overbye K, Aasland HW, Walhovd KB (2014). Differential longitudinal changes in cortical thickness, surface area and volume across the adult life span: regions of accelerating and decelerating change. *Journal of Neuroscience* **34**, 8488–8498.
- Szeszko PR, Narr KL, Phillips OR, McCormack J, Sevy S, Gunduz-Bruce H, Kane JM, Bilder RM, Robinson DG

- (2012). Magnetic resonance imaging predictors of treatment response in first-episode schizophrenia. *Schizophrenia Bulletin* **38**, 569–578.
- Takao H, Hayashi N, Ohtomo K** (2013). Effects of the use of multiple scanners and of scanner upgrade in longitudinal voxel-based morphometry studies. *Journal of Magnetic Resonance Imaging* **38**, 1283–1291.
- Tan H-Y, Sust S, Buckholtz JW, Mattay VS, Meyer-Lindenberg A, Egan MF, Weinberger DR, Callicott JH** (2006). Dysfunctional prefrontal regional specialization and compensation in schizophrenia. *American Journal of Psychiatry* **163**, 1969–1977.
- Thambisetty M, Wan J, Carass A, An Y, Prince JL, Resnick SM** (2010). Longitudinal changes in cortical thickness associated with normal aging. *NeuroImage* **52**, 1215–1223.
- Tognin S, Riecher-Rössler A, Meisenzahl EM, Wood SJ, Hutton C, Borgwardt SJ, Koutsouleris N, Yung AR, Allen P, Phillips LJ, McGorry PD, Valli I, Velakoulis D, Nelson B, Woolley J, Pantelis C, McGuire P, Mechelli A** (2014). Reduced parahippocampal cortical thickness in subjects at ultra-high risk for psychosis. *Psychological Medicine* **44**, 489–498.
- Van Haren NEM, Hulshoff Pol HE, Schnack HG, Cahn W, Brans R, Carati I, Rais M, Kahn RS** (2008). Progressive brain volume loss in schizophrenia over the course of the illness: evidence of maturational abnormalities in early adulthood. *Biological Psychiatry* **63**, 106–113.
- Van Haren NEM, Schnack HG, Cahn W, Van den Heuvel MP, Lepage C, Collins L, Evans AC, Pol HEH, Kahn RS** (2011). Changes in cortical thickness during the course of illness in schizophrenia. *Archives of General Psychiatry* **68**, 871–880.
- Venkatasubramanian G, Jayakumar PN, Gangadhar BN, Keshavan MS** (2008). Automated MRI parcellation study of regional volume and thickness of prefrontal cortex (PFC) in antipsychotic-naïve schizophrenia. *Acta Psychiatrica Scandinavica* **117**, 420–431.
- Veronese E, Castellani U, Peruzzo D, Bellani M, Brambilla P** (2013). Machine learning approaches: from theory to application in schizophrenia. *Computational and Mathematical Methods in Medicine* DOI: 10.1155/2013/867924.
- Vita A, Peri LD, Deste G, Sacchetti E** (2012). Progressive loss of cortical gray matter in schizophrenia: a meta-analysis and meta-regression of longitudinal MRI studies. *Translational Psychiatry* **2**, e190.
- Weinberger DR, McClure RK** (2002). Neurotoxicity, neuroplasticity, and magnetic resonance imaging morphometry: what is happening in the schizophrenic brain? *Archives of General Psychiatry* **59**, 553–558.
- Xiao Y, Lui S, Deng W, Yao L, Zhang W, Li S, Wu M, Xie T, He Y, Huang X, Hu J, Bi F, Li T, Gong Q** (2015). Altered cortical thickness related to clinical severity but not the untreated disease duration in schizophrenia. *Schizophrenia Bulletin* **41**, 201–210.
- Yoon U, Lee J-M, Im K, Shin Y-W, Cho BH, Kim IY, Kwon JS, Kim SI** (2007). Pattern classification using principal components of cortical thickness and its discriminative pattern in schizophrenia. *NeuroImage* **34**, 1405–1415.
- Zarogianni E, Moorhead TWJ, Lawrie SM** (2013). Towards the identification of imaging biomarkers in schizophrenia, using multivariate pattern classification at a single-subject level. *NeuroImage: Clinical* **3**, 279–289.
- Zhang Y, Lin L, Lin C-P, Zhou Y, Chou K-H, Lo C-Y, Su T-P, Jiang T** (2012). Abnormal topological organization of structural brain networks in schizophrenia. *Schizophrenia Research* **141**, 109–118.
- Zipparo L, Whitford TJ, Redoblado Hodge MA, Lucas S, Farrow TFD, Brennan J, Gomes L, Williams LM, Harris AWF** (2008). Investigating the neuropsychological and neuroanatomical changes that occur over the first 2–3 years of illness in patients with first-episode schizophrenia. *Progress in Neuro-Psychopharmacology & Biological Psychiatry* **32**, 531–538.
- Zipursky RB, Reilly TJ, Murray RM** (2013). The myth of schizophrenia as a progressive brain disease. *Schizophrenia Bulletin* **39**, 1363–1372.