

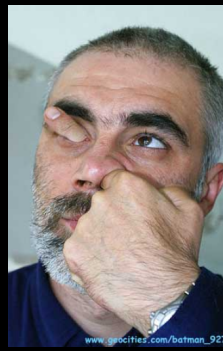# Ocular Trauma

Nathan Lambert, MD  
Ophthalmology Resident  
Casey Eye Institute



Bad things happen...

...sometimes it's his fault

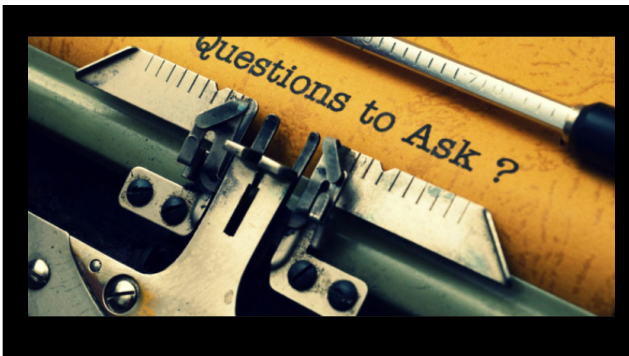
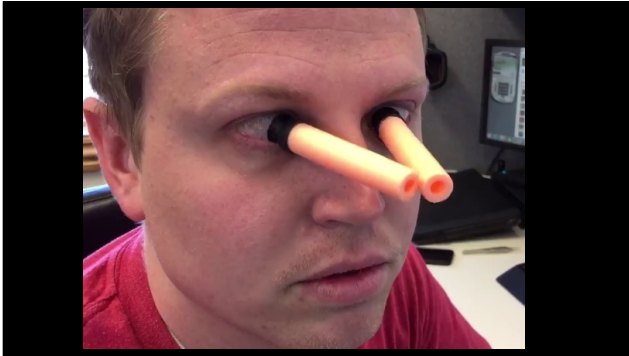
Sometimes it's your fault...



Sometimes it's the other guy's...





**Objectives**

- Understand different types of ocular trauma
- Understand how to triage ocular injuries
- Know what to tell people to do, and when to be evaluated

**Bad eye injury in**



**3...2...1..**

**24 year old Female...**

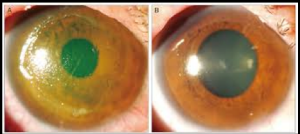
- Contact lens wearer
- Woke up with pain, redness, blurry vision, and light sensitivity

**Ddx:**

Kahoot #1

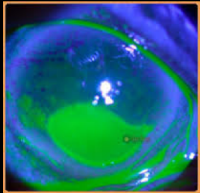
**Epithelial Defect**

- 24 year old Female
- Contact lens wearer
- Woke up with pain, redness, blurry vision, and light sensitivity



**Epithelial Defect**


- Fluorescein highlights the defect
- Numbing agent reduces the pain significantly



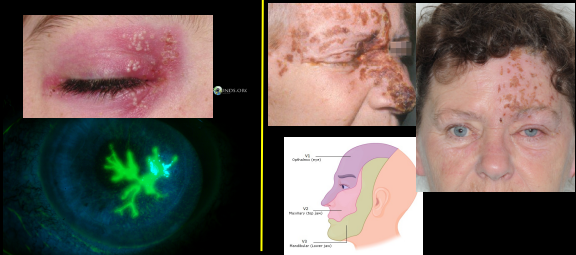
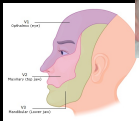
**Ddx:** corneal epithelial defect vs ?

**Differential diagnoses to consider...**

HERPES (HSV, VZV)



**Herpes Simplex (HSV)**      **Herpes Zoster (VZV)**

**Differential diagnoses to consider...**

**CORNEAL ULCER** =  
Epi defect + Infiltrate/stromal haze

- Bacterial >>> fungal



**BACTERIAL ULCER WITH HYPOPYON**

HYPOPYON

Can have hypopyon in severe cases

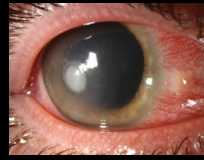
## Corneal Ulcers

### Culture

- BEFORE starting antibiotics

### TREATMENT

- Topical antibiotics (fluoroquinolone)
  - Ofloxacin/Ciprofloxacin
  - Vigamox (Moxifloxacin)
- If LARGE (2mm) or CENTRAL – start FORTIFIED antibiotics
  - Vancomycin and Tobramycin



## Acanthamoeba

### SIGNS/SYMPTOMS:

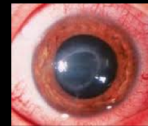
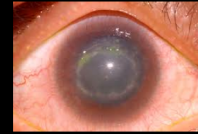
- SEVERE eye pain (out of proportion)
- History of mountain water exposure
- Consider in any patient with soft contact use
- Redness, photophobia over weeks
- Later – ring shaped stromal infiltrate

### DIAGNOSIS:

- Bacterial cultures are NEGATIVE
- Cysts on confocal microscopy

### TREATMENT

- Does NOT respond to antibiotics
- Chlorhexidine



## Epithelial Defect

### QUESTIONS

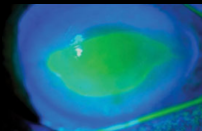
- Contact lens use?
- Trauma?
- Foreign body?
- Rash?

### EXAM

- Fluorescein (distribution?)
- Facial Rash
- Infiltrate

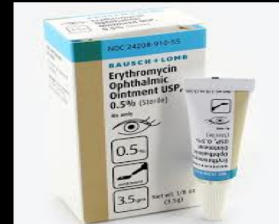### Ddx:

- Abrasion
- Herpetic
- Ulcer



## Regular of' Epithelial defect

- Mainstay of treatment is erythromycin ointment.
- Never start with a steroid, avoid Maxitrol.



## 40 year old male...

- Janitor at school
- Got some cleaning material in eye
- Pain and blurry vision

**What should he do next?**



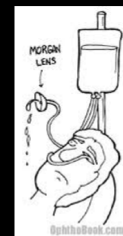### CHEMICAL BURN

#### CALL

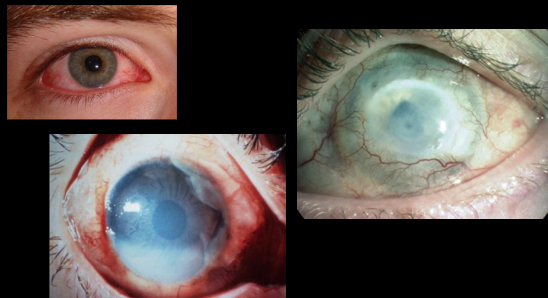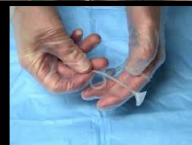- 40 year old M, janitor at school
- Got some cleaning material in eye

### History

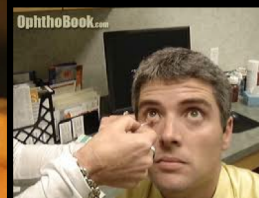- What chemical?
- When was exposure?



ADVICE?  
RINSE  
RINSE  
RINSE  
RINSE

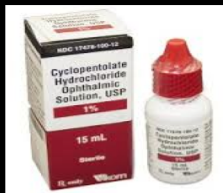

### pH strips



### Chemical Burn-- Treatment

- Mild to moderate: Erythromycin Q1-2 hours
- +/- Cycloplegic
- +/- IOP lowering therapy if indicated
- Severe: may also require topical steroids
- +/- topical abx gtt
- +/- BCL, pressure patch
- Consider:
  - Oral Doxycycline 100 mg PO BID
  - Vitamin C 1000 mg daily
- Follow up: daily initially



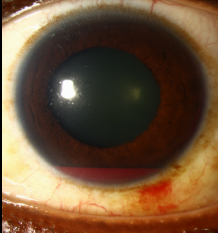
### Chemical Burn

#### QUESTIONS

- When?
- What?

**RINSE!!!**

**Kahoot #3**



**9 year old boy...**


- Playing NERF wars with brother
- Nerf arrow shot him in the eye
- Pain in the eye, very light sensitive, vision is “kinda blurry”

**Hyphema**

- 9 year old boy playing NERF wars with brother – nerf arrow shoot him in the eye
- Pain in the eye, very light sensitive, vision is “kinda blurry”



**Hyphema Treatment**



- Keep head elevated
- No Aspirin, Ibuprofen, blood thinners
- Consider sickle prep– assess risk
- Shield– protect the eye
- Cycloplegic for pain
- Bed rest!
- Close follow up (daily initially)
- High risk of re-bleed!
- May require surgical evacuation if not resolving, IOP spike occurs, or corneal blood staining occurs

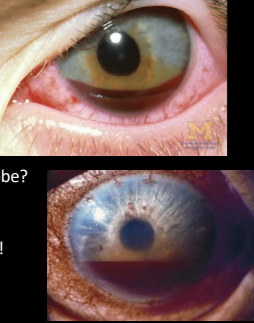
**Hyphema**

**QUESTIONS**

- Mechanism of trauma?
- Photophobia
- Potential foreign body?
- Flashes/Floaters?
- Sickle cell disease?

**EXAM**

- Ruptured globe?
- How tall hyphema?
- Eye Pressure!



**Subconjunctival Hemorrhage**

Patient calls in and says “My eye bleeding!”



**Questions to ask:**

- Pain?
- Redness (the white part)? Or there is blood coming from eye?
- Hx/o trauma? Prev surgery?

**Risk Factors**

- Blood thinners
- Age
- High blood pressure
- Coughing
- Valsalva

Often resolve over 2-3weeks



**Kahoot**

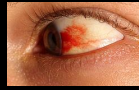**60 year old Female...**

Woke up and noticed eye was “all red”!

- History of atrial fibrillation and high blood pressure
- Currently has an upper respiratory infection
- No change to vision
- No pain, irritation, or light sensitivity
- No recent trauma
- No previous surgery

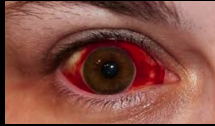### Subconjunctival Hemorrhage

Patient calls in and says "My eye bleeding!"



#### Questions to ask:

- Pain?
- Redness (the white part? Or there is blood coming from eye?)
- Hx/o trauma? Prev surgery?

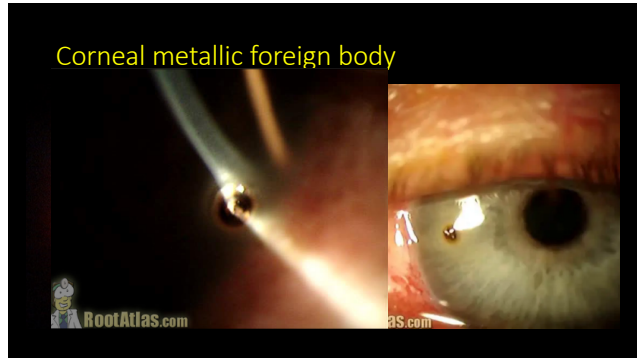


#### Risk Factors

- Blood thinners
- Age
- High blood pressure
- Coughing
- Valsalva

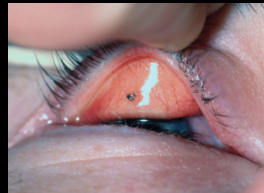Often resolve over 2-3 weeks

### Corneal metallic foreign body



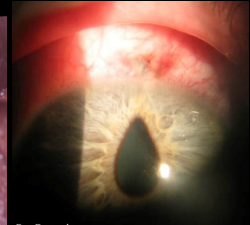
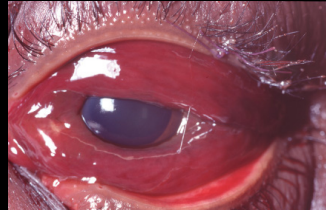### Corneal metallic foreign body

- Mechanism of injury
- Size, weight, velocity, force of object
- Document VA *before* any procedure is performed
- Check under lids!



### Kahoot

These are two findings of ...?

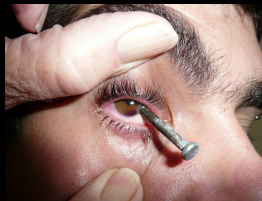

EyeRounds.org

### Kahoot

35yo M, construction worker...

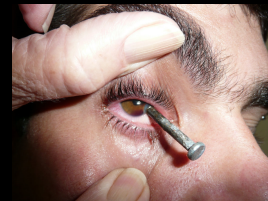- Using nail gun, when...



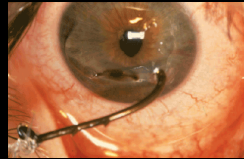
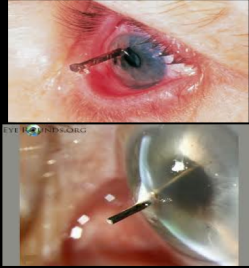
### Ruptured Globe

35yo M, construction worker...

- Using nail gun, when...



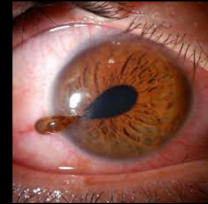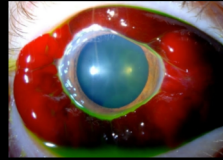
### Penetrating globe injury



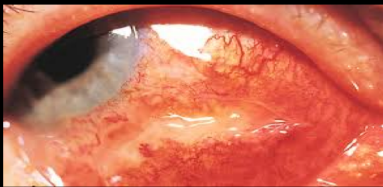
**Do NOT remove**

....need operating room

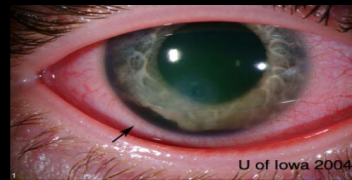### Ruptured globe – not so obvious



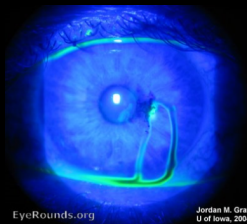
### Ruptured globe – check the conjunctiva



### Ruptured globe – check the limbus

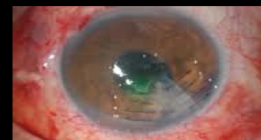

### Ruptured globe – check cornea



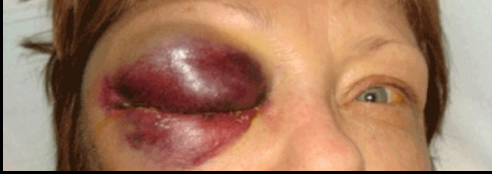### Ruptured Globe Initial Response

- CT Head/orbits
- IV Antibiotics (400 mg IV Moxifloxacin preferred– best vitreous penetration)
- Shield
- Tetanus
- Antiemetic
- Pain control
- Rest
- NPO!
- Call for urgent surgical evaluation



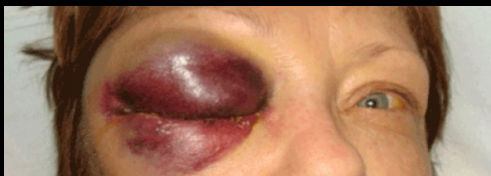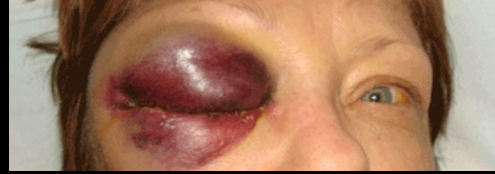Kahoot

69yo Female, falls while walking up the stairs to your clinic...



Retrobulbar hemorrhage

69yo Female, falls while walking up the stairs to your clinic...

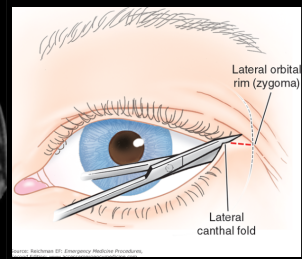
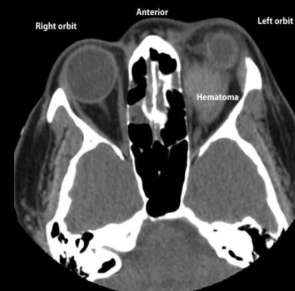

QUESTIONS

- Mechanism of trauma?
- Blood thinners?
- Flashes/Floaters?

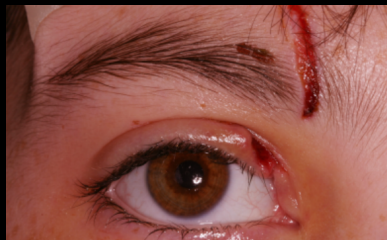EXAM

- Ruptured globe?
- Afferent pupillary defect (APD)
- Motility
- Eye Pressure

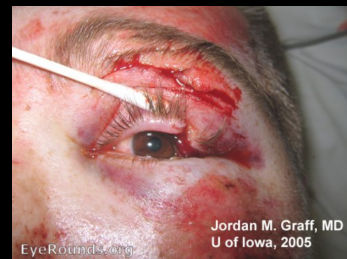

Kahoot

10 year girl...  
•dog bite to face...

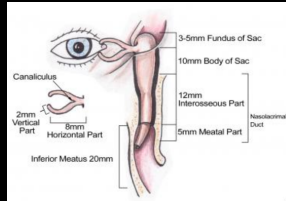
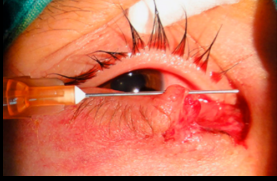


Eyelid laceration





## Eyelid laceration



### QUESTIONS

- Mechanism of trauma? (dog bite, fall, knife, etc)
- Double vision?

### EXAM

- Ruptured globe?
- Motility
- Canalicular involvement

## Conclusion

- Eye injuries can occur in a variety of ways
- Important to know how triage ocular injuries
- Know what to tell people to do, and when to be evaluated

