

A histological section of skin, stained with hematoxylin and eosin (H&E). The image shows the epidermis at the top, characterized by a stratified squamous epithelium with a prominent granular layer. Below the epidermis is the dermis, which contains a dense network of collagen fibers and various cellular components, including fibroblasts and small blood vessels. The overall structure is typical of mammalian skin.

# Ребусы на тему «Кожа»

Составитель:  
Черпитяк Т.Б  
МОУ «Школа  
№91 г. Донецка»



Ответ



“



”

Ответ



”

 4 = T



Ответ

”



”

Ответ



Ответ




,



”””



Ответ



“



”

Ответ





””



”

,



”

Ответ



“



1 = A

”

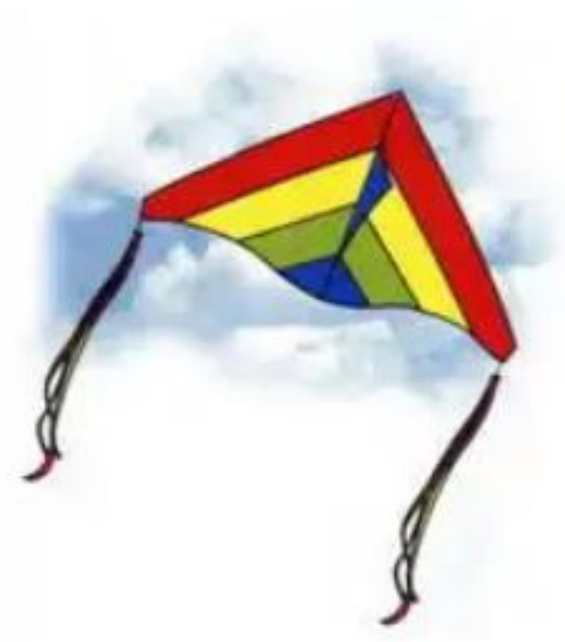

CBETA

2

Ответ

,



’



1 = Л



Ответ