

FORENSIC ASSOCIATES OF NEPA
1008 LEWIS LANE
CLARKS SUMMIT, PA 18411
570-561-5786
forensics.nepa@gmail.com

NAME: Randy Robert Stair

AUTOPSY NO: FA-2017-A-149

CASE TYPE: Forensic

AGE: 24 **DOB:** 9/17/1992 **RACE:** White **SEX:** Male

DATE/TIME OF AUTOPSY: June 9, 2017 @ 0900 hours

AUTOPSY PERFORMED AT: Northeast Forensic Center, Dunmore, Pennsylvania

REPORTED DATE/TIME OF DEATH: June 8, 2017 @ 0220 hours

AUTOPSY AUTHORIZED BY: Thomas Kukuchka, Wyoming County Coroner

LIMITATIONS: External examination only

BODY IDENTIFICATION: I.D. Tag Coroner

AUTOPSY PERFORMED BY: Gary W. Ross, M.D.

PERSONS PRESENT AT AUTOPSY: Al Hughes, Autopsy Assistant
Eric Kukuchka, Chief Deputy Wyoming County Coroner
Sean Cooney, Pennsylvania State Police
Chris Wilson, Pennsylvania State Police
Timothy Rowland, Lackawanna County Coroner
Jim O'Malley, Lackawanna Mobile X-ray
Paul Woelkers, Lackawanna Mobile X-ray

INVESTIGATIVE POLICE JURISDICTION: Pennsylvania State Police

AUTOPSY COMPLETION DATE: July 23, 2017

PATHOLOGIC DIAGNOSES:

GENERAL HISTORY:

History of gender dysphoria.
History of killing three co-workers prior to his suicide.

EXTERNAL EXAMINATION:

Intraoral shotgun wound of entrance.
Soot right index finger base.
Ecchymosis webspace 1st and 2nd digits, right hand.
Black make-up lateral orbits and lips.
Shaved body and extremity hair.

MEDICATIONS:

None known at time of autopsy.

TOXICOLOGY: Postmortem blood: Diphenhydramine: 372 ng/ml


CAUSE OF DEATH: Shotgun Wound of Head (Entrance Mouth)

MANNER OF DEATH: Suicide

FINAL SUMMARY: The decedent was a 24-year-old white male who shot three co-workers at Weiss Market in Tunkhannock, Pennsylvania then shot himself. Pistol type shotgun used for all three murders and his suicide. This decedent sustained an intraoral shotgun wound of entrance. Trajectory front to back, upward through the anterior maxilla, soft palate and skull. Extrusion of copious brain matter occipitally. Blood smears and spatter left hand. Soot base of right index finger. Ecchymosis right thumb and index webspace. Copious soot intraorally. Black make-up external lips and orbits laterally (black makeup in car). Decedent clothed in female garments beneath his male clothes. Body hair shaved. Multiple recovered bullets and was given directly to Sean Cooney of the Pennsylvania State Police.

DESCRIPTION OF SHOTGUN WOUND

Within the oral cavity is a shotgun wound on the upper midjaw centrally $\frac{3}{4}$ x $\frac{3}{4}$ ". The two upper front teeth are absent. The wound extends upward, front to back through the hard palate with copious soot about the wound, within the oral cavity and on the external lips. The wound is directed front to back, upward with a massive exit occipitally 5 x 4" with extensive loss of brain and skull extruded. Blood smeared and spattered on left hand. This wound was lethal in and of itself.


Gary W. Ross, M.D.
Forensic Pathologist

Preliminary Date: June 12, 2017

Final Date: July 23, 2017

GWR/sc

FORENSIC ASSOCIATES OF NEPA
1008 LEWIS LANE
CLARKS SUMMIT, PA 18411
570-561-5786
forensics.nepa@gmail.com

NAME: Brian Hayes

AUTOPSY NO: FA-2017-A-152

CASE TYPE: Forensic

AGE: 47 **DOB:** 12/17/1969 **RACE:** White **SEX:** Male

DATE/TIME OF AUTOPSY: June 9, 2017 @ 1200 hours

AUTOPSY PERFORMED AT: Northeast Forensic Center, Dunmore, Pennsylvania

REPORTED DATE/TIME OF DEATH: June 8, 2017 @ approximately 0200 hours

AUTOPSY AUTHORIZED BY: Thomas Kukuchka, Wyoming County Coroner

LIMITATIONS: External examination only

BODY IDENTIFICATION: I.D. Tag Coroner

AUTOPSY PERFORMED BY: Gary W. Ross, M.D.

PERSONS PRESENT AT AUTOPSY: Al Hughes, Autopsy Assistant
Eric Kukuchka, Chief Deputy Wyoming County Coroner
Sean Cooney, Pennsylvania State Police
Chris Wilson, Pennsylvania State Police
Tim Rowland, Lackawanna County Coroner
Jesse VanDeusen, Chief Deputy Lackawanna County Coroner
Lou Stefanelli, Deputy Lackawanna County Coroner
Jim O'Malley, Lackawanna Mobile X-ray
Paul Woelkers, Lackawanna Mobile X-ray

INVESTIGATIVE POLICE JURISDICTION: Pennsylvania State Police

AUTOPSY COMPLETION DATE: June 20, 2017

BRIAN HAYES

FA-2017-A-152

PATHOLOGIC DIAGNOSES:

GENERAL HISTORY:

History of being shot by another.

EXTERNAL EXAMINATION:

Multiple shotgun wounds x5.
Poor dentition.

TOXICOLOGY: Deferred

CAUSE OF DEATH: Multiple Shotgun Wounds (Five)

MANNER OF DEATH: Homicide

FINAL SUMMARY: The decedent was a 47-year-old white male night manager at Weiss Market, Tunkhannock, Pennsylvania shot five times by a co-worker Randy Stair FA-2017-A-149 who then shot himself and two others. This decedent sustained shot wounds to his head, chest, right flank, groin and left arm. Wounds were lethal. Multiple recovered wads and pellets given directly to Sean Cooney of the Pennsylvania State Police.



Gary W. Ross, M.D.
Forensic Pathologist

Preliminary Date: June 13, 2017

Final Date: June 20, 2017

GWR/sc

DESCRIPTION OF SHOTGUN WOUND #1

On the right side of the head just superior to the right orbit is a distant shotgun wound of entrance without soot or stippling. Trajectory is from front to back, right to left resulting in massive scalp tears, skull fractures and almost complete extrusion of brain matter from the skull. This wound is lethal in and of itself.

DESCRIPTION OF SHOTGUN WOUND #2

On the upper midchest at the suprasternal area is a 1 ¼ x 1 ¼" distant shotgun wound of entrance with a 1 ¼ x 3/8" margin of abrasion at 7 to 12 o'clock and associated abrasion of the midupper neck 3 x 1". Pellets directed from right to left, slightly upward, front to back. Wad recovered from the wound. Five exit wounds of the left posterior arm and shoulder. Two pellets recovered in adjacent region in subcutaneous tissue. This wound is lethal in and of itself. Wad and pellets given directly to Sean Cooney of the Pennsylvania State Police.

DESCRIPTION OF SHOTGUN WOUND #3

On the right lower flank is a 1 ¼" distant shotgun wound of entrance without soot or stippling. No scalloping of the margin. Bowel protrudes from the wound. Pellets directed horizontally, right to left, through the abdomen with five exit wounds in the left lower flank, each 3/8". Two pellets recovered in subcutaneous tissue. This wound is lethal in and of itself. Pellets given directly to Sean Cooney of the Pennsylvania State Police.

DESCRIPTION OF SHOTGUN WOUND #4

On the midgroin region is a 1" distant shotgun wound of entrance with extensive skin tearing. Base of penis with numerous tears. Wound is directed from front to back, left to right. A plastic wad is recovered in the anterior groin soft tissue. Two pellet exit wounds are identified in the left lateral thigh along with two skin abrasions. This wound is potentially lethal. The wad was given directly to Sean Cooney of the Pennsylvania State Police.

DESCRIPTION OF SHOTGUN WOUND #5

On the left lower arm laterally are three shotgun wound pellet entrances, each 3/8" in diameter with adjacent 3/8" exit wounds located 1" more medially. Pellets travel through soft tissues. This wound is not lethal.

FORENSIC ASSOCIATES OF NEPA
1008 LEWIS LANE
CLARKS SUMMIT, PA 18411
570-561-5786
forensics.nepa@gmail.com

NAME: Terry Lee Sterling

AUTOPSY NO: FA-2017-A-151

CASE TYPE: Forensic

AGE: 63 **DOB:** 4/3/1954 **RACE:** White **SEX:** Male

DATE/TIME OF AUTOPSY: June 9, 2017

AUTOPSY PERFORMED AT: Northeast Forensic Center, Dunmore, Pennsylvania

REPORTED DATE/TIME OF DEATH: June 8, 2017 @ 0205 hours

AUTOPSY AUTHORIZED BY: Thomas Kukuchka, Wyoming County Coroner

LIMITATIONS: External examination only

BODY IDENTIFICATION: I.D. Tag Coroner

AUTOPSY PERFORMED BY: Gary W. Ross, M.D.

PERSONS PRESENT AT AUTOPSY:

- Al Hughes, Autopsy Assistant
- Eric Kukuchka, Chief Deputy Wyoming County Coroner
- Sean Cooney, Pennsylvania State Police
- Chris Wilson, Pennsylvania State Police
- Tim Rowland, Lackawanna County Coroner
- Jesse VanDeusen, Chief Deputy Lackawanna County Coroner
- Lou Stefanelli, Deputy Lackawanna County Coroner
- Jim O'Malley, Lackawanna Mobile X-ray
- Paul Woelkers, Lackawanna Mobile X-ray

INVESTIGATIVE POLICE JURISDICTION: Pennsylvania State Police

AUTOPSY COMPLETION DATE: June 20, 2017

TERRY LEE STERLING

FA-2017-A-151

PATHOLOGIC DIAGNOSES:

GENERAL HISTORY:

History of being shot by another.

EXTERNAL EXAMINATION:

Multiple shotgun wounds x2.

Adentulous.

TOXICOLOGY: Deferred

CAUSE OF DEATH: Multiple Shotgun Wounds (Two)

MANNER OF DEATH: Homicide

FINAL SUMMARY: The decedent was a 63-year-old white male shot x2 by Randy Stair FA-2017-A-149 a co-worker at Weiss Market in Tunkhannock, Pennsylvania. Decedent sustained two shotgun wounds. One to the upper back and a second to the left shoulder. Multiple exit wounds in neck. Multiple pellets in head, neck and chest by postmortem x-ray. No defensive injuries. Each of these wounds was lethal.

Cause of death: Multiple shotgun wounds (two). Manner of death: Homicide.

DESCRIPTION OF SHOTGUN WOUND #1

On the upper right back is a distant shotgun wound of entrance without soot or stippling. Margin of abrasion at 5 o'clock $\frac{3}{4}$ x $\frac{1}{2}$ ". Trajectory right to left, back to front, upward with multiple exit wounds in left neck. Wound is lethal in and of itself.

DESCRIPTION OF SHOTGUN WOUND #2

On the left shoulder is a distant 1 $\frac{1}{4}$ " shotgun wound of entrance. No soot or stippling surrounds the wound. Left humeral head transected. Pellets travel from left to right, upward, back to front. Several exit wounds on neck. Wound is lethal in and of itself.



Gary W. Ross, M.D.

Forensic Pathologist

Preliminary Date: June 13, 2017

Final Date: June 20, 2017

GWR/sc

FORENSIC ASSOCIATES OF NEPA
1008 LEWIS LANE
CLARKS SUMMIT, PA 18411
570-561-5786
forensics.nepa@gmail.com

NAME: Victoria Todd Brong

AUTOPSY NO: FA-2017-A-150

CASE TYPE: Forensic

AGE: 25 **DOB:** 8/10/1991 **RACE:** White **SEX:** Female

DATE/TIME OF AUTOPSY: June 9, 2017 @ 1000 hours

AUTOPSY PERFORMED AT: Northeast Forensic Center, Dunmore, Pennsylvania

REPORTED DATE/TIME OF DEATH: June 8, 2017 @ 0210 hours

AUTOPSY AUTHORIZED BY: Thomas Kukuchka, Wyoming County Coroner

LIMITATIONS: External examination only

BODY IDENTIFICATION: I.D. Tag Coroner

AUTOPSY PERFORMED BY: Gary W. Ross, M.D.

PERSONS PRESENT AT AUTOPSY: Al Hughes, Autopsy Assistant
Eric Kukuchka, Chief Deputy Wyoming County Coroner
Thomas Kukuchka, Wyoming County Coroner
Sean Cooney, Pennsylvania State Police
Chris Wilson, Pennsylvania State Police
Tim Rowland, Lackawanna County Coroner
Jesse VanDeusen, Chief Deputy Lackawanna County Coroner
Lou Stefanelli, Deputy Lackawanna County Coroner
Jim O'Malley, Lackawanna Mobile X-ray
Paul Woelkers, Lackawanna Mobile X-ray

INVESTIGATIVE POLICE JURISDICTION: Pennsylvania State Police

AUTOPSY COMPLETION DATE: June 20, 2017

PATHOLOGIC DIAGNOSES:

GENERAL HISTORY:

History of being shot by another.

EXTERNAL EXAMINATION:

Multiple shotgun wounds x4.

TOXICOLOGY: Deferred

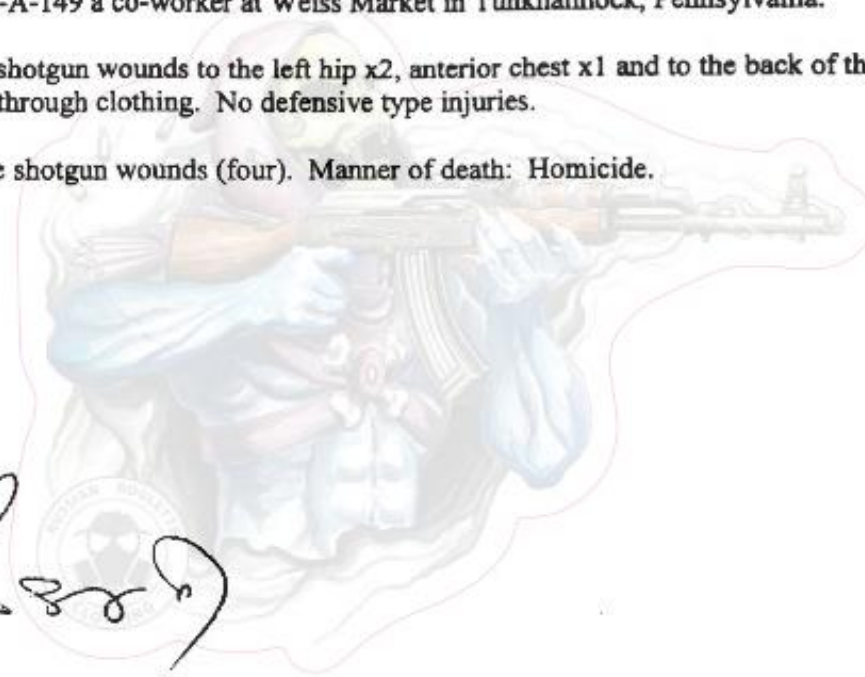
CAUSE OF DEATH: Multiple Shotgun Wounds (Four)

MANNER OF DEATH: Homicide

FINAL SUMMARY: The decedent was a 25-year-old white female shot four times with a pistol shotgun by Randy Stair FA-2017-A-149 a co-worker at Weiss Market in Tunkhannock, Pennsylvania.

This decedent sustained shotgun wounds to the left hip x2, anterior chest x1 and to the back of the head x1. All wounds distant. All through clothing. No defensive type injuries.

Cause of death: Multiple shotgun wounds (four). Manner of death: Homicide.



Gary W. Ross, M.D.

Forensic Pathologist

Preliminary Date: June 13, 2017

Final Date: June 20, 2017

GWR/sc

DESCRIPTION OF SHOTGUN WOUND #1

On the midupper posterior neck at the base of the skull is a distant 1 ¼" shotgun wound of entrance. Trajectory is from back to front, upward slightly toward the right. Extensive scalp tearing and skull fracturing. Brain extensively torn. Multiple metallic fragments within skull by x-ray. This wound was lethal in and of itself.

DESCRIPTION OF SHOTGUN WOUND #2

On the anterior chest is a distant shotgun wound of entrance creating multiple entry, exit and re-entry wounds. Central 1" and ¾" entry/exit pellet and wad entry wounds. Five pellet wounds left medial breast and five of right medial breast with five exits each 3/8" right lateral chest. Trajectory left to right, horizontal. This wound is lethal in and of itself.

DESCRIPTION OF GUNSHOT WOUND #3

On the left hip is a distant shotgun wound of entrance ¾ x 6". Abrasion margin at 6 o'clock. Pellets directed upward, slightly front to back with numerous exit wounds on left lateral flank. Plastic wad recovered in left flank soft tissue. Wound is potentially lethal.

DESCRIPTION OF SHOTGUN WOUND #4

On the left lateral hip is a distant shotgun wound of entrance ¾" in diameter with an abrasion margin at 9 o'clock. Pellets directed from left to right with multiple exit and re-entry wounds across the upper buttocks each about 1/4 to 3/8" in diameter. Wad recovered in the subcutaneous tissue of left buttock. This wound is potentially lethal.