

Trapped Fingers and Amputated Finger Tips in Children

By Cynthia M. Illingworth

IN THE ACCIDENT AND EMERGENCY Department of the Children's Hospital, Sheffield, we see each year between 300 and 350 trapped fingers. The management of this injury has been modified with experience. We now know that spontaneous regeneration and excellent cosmetic and functional results can be obtained in guillotine amputations of finger tips in young children.

REVIEW OF THE LITERATURE

Many experiments have been made on animals in an attempt to produce regrowth of an amputated part. In the larval stage a salamander can regenerate a forelimb in 30–40 days, but the adult takes longer and the regenerated limb is short. In froglets the degree of regeneration depended on the stage of development—the younger the froglet the greater was the regeneration.¹ Regeneration was greater in the distal parts. Opossums were used as experimental animals² because they are in an early stage of development at birth. Regeneration of the limb occurred if they implanted nervous tissues into the proximal part of the limb before amputation. Others^{3,4} have shown that regeneration is dependent on the presence of a critical amount of nervous tissue in the amputation stump and that if this is reduced, as in the salamander by cutting the nerve proximally, the limbs will not regenerate until nerves grow into this area. When animals such as reptiles or mature frogs had lost their ability to regrow limbs, regeneration could be induced by nerve implants—suggesting that they possessed a latent regenerative capacity. It is thought that the nervous tissue provides data transmission and control systems which control the growth processes involved in repair.

Electrical field charges have been demonstrated in experimental animals during the healing process. Becker⁵ and Becker and Spadaro⁶ showed that partial limb regeneration could be induced in rats by applying appropriate levels of electrical stimulation to simulate the “current of injury” which occurs in forms which can regenerate.

Several writers⁷ have shown that the hormone prolactin is important for limb regeneration; they have suggested that it sensitizes appropriate cells to the electrical charge of the “current of injury.”

Becker and Murray⁸ showed that dedifferentiation of nucleated red cells in the hematoma of fractures in amphibia is important for healing, and that dedifferentiation could be produced in normal nucleated red cells by extremely low levels of electrical currents similar to that occurring at the site of injury. More recently, small circulating mammalian lymphocytes have been exposed to

From the Accident and Emergency Department, The Children's Hospital, Sheffield, England.

Address for reprint requests: Cynthia M. Illingworth, Accident and Emergency Department, Children's Hospital, Sheffield 10, England.

© 1974 by Grune & Stratton, Inc.

phytohemagglutinin so that they are transformed into a more primitive form.⁹ This is thought to be true dedifferentiation. It is thought that transformation to more primitive cell types enables the cell to redifferentiate in different ways, dependant on local factors.

Becker¹⁰ is using techniques of electrical bone stimulation in an attempt to promote healing in adults with persistent nonunion of fractures. In a small series he has a success rate of more than 50% in cases in which other types of therapy have failed.

Becker¹¹ wrote that "regeneration of lost body parts is an ability shared to a varying degree by all living things. In the evolutionary sequence, the ability be-gradually decreased. In a child, the diaphysis of a long bone can regenerate provided that the periosteal tube is intact, but, in an adult, a fracture heals by replacement with functional osseous tissue." He considered that important factors are nutrition, vascularity, and immobilization, but that the basic cell dedifferentiation and subsequent redifferentiation to produce a replica of the missing bone represents true tissue regeneration. Becker¹² gave an excellent review of recent research in the field of regenerative healing in man.

PRESENT INVESTIGATION

The 300-350 cases of trapped fingers seen by us each year include all degrees of severity, the most severe ones consisting of complete amputation of the tip. We have adopted simple methods of dealing with them, which are completely effective and which inflict very little discomfort. We never suture trapped fingers; they are held in position by Steristrip or Ethistrip, covered by a nonstick dressing and a mitten-type bandage and reviewed for the first time after a week. The strips are removed after 2 wk when almost all the fingers are healed; the results are excellent. No antibiotics are given.

Where the tip has been amputated completely, the methods have changed gradually over the last 6 yr and they have proved an extremely interesting field of study. Originally, whenever possible the separated tip was retrieved, was anchored usually by one suture and then treated like other trapped fingers. If the tip was not available, a small graft was applied if it appeared as if the pulp was sufficiently intact to receive it. If the bone of the terminal phalanx protruded, it was shortened and a surgical tidying up procedure performed. All these manoeuvres involved anesthesia of some kind—usually a general anesthetic, as most of the children were too small to make local anesthesia satisfactory. When the separated tips were reapplied they all did surprisingly well. One day, owing to a misunderstanding, a child with a guillotine amputation of finger tip, whom the Senior House Officer had intended to refer to a plastic surgeon, had the finger covered with a simple dressing, and in error was not seen again for several days. The finger was healing beautifully and there was eventually complete regrowth of the tip. We now know that this happens in young children. Some months afterwards I found that this had also been noticed in Australia.^{13,14}

Even when the bone protrudes, nothing at all is done except gentle cleaning of the area, which is then covered with thick layer of Tulle-gras and a mitten bandage. It is left alone for about a fortnight. The parents are warned that it

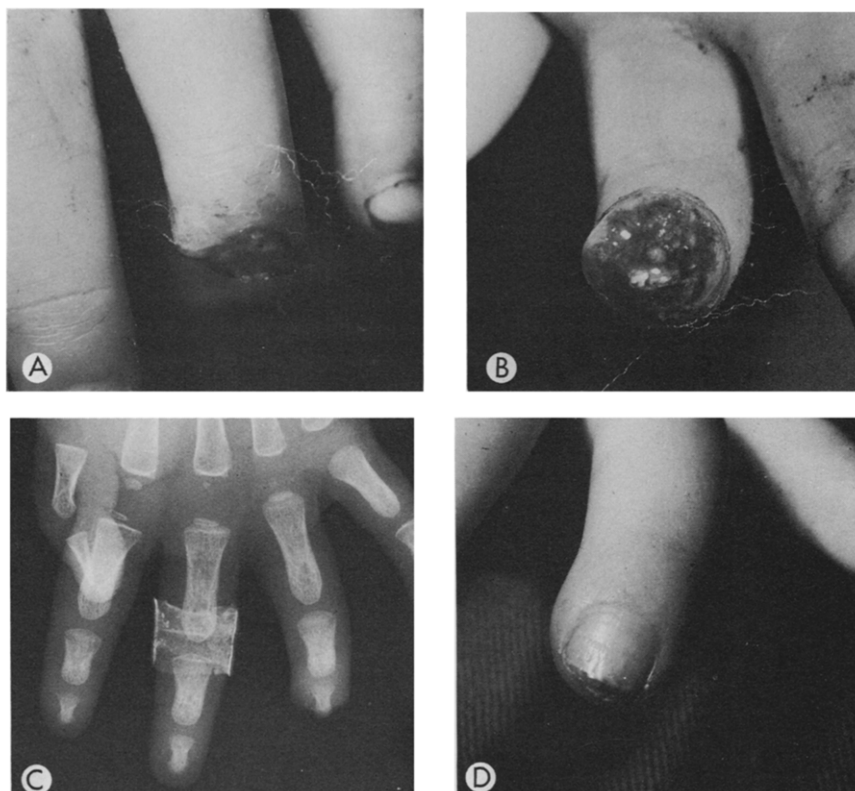


Fig. 1. (A), (B) Guillotine amputation of finger tip in child of 1 yr 10 mo. (C) X-Ray. (D) Eleven weeks after accident.

will look awful at the first dressing, but that the results will be excellent. No antibiotics are given. About three or four dressing are required, and, after the first two, the intervals between dressing are increased, usually to 4 wk. Full repair in a young child takes about 11 or 12 wk. We have treated dozens of cases by this method with consistently good results. Figures 1-3 show the results obtained in typical cases, the restoration of length, contour, and function. Even the finger whorls are remarkably restored.

The results are so good that, when recently we had a child referred for follow-up after surgical treatment in another city, all the nursing and medical staff of the department were greatly upset by the appearance, by the child's discomfort on having the sutures removed, and by the mother's distress at the sight of the shortened finger. Although the terminal phalanx had been shortened and the finger-tip sutured proximal to the nail-bed, there has been regrowth of the nail and the cosmetic result is poor (Fig. 4)

DISCUSSION

Parents are greatly distressed when their young children trap their fingers, especially if the whole of the finger tip has been amputated or part of the finger end is hanging by a flap of skin. They feel particularly guilty about this type of

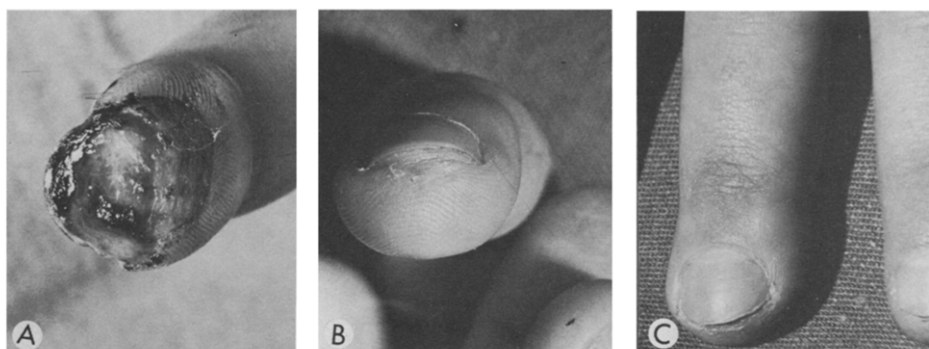


Fig. 2. (A) Amputation of finger tip in 5-yr-old girl. (B), (C) Twelve weeks after accident.

injury partly because the children are so young (two-thirds being under 4 yr of age) and partly because they feel responsible for the injury. It is of the greatest importance that the child's visit to hospital should be painless and that active surgery should be avoided if possible.

We have been grading the levels of tissue loss (Fig. 5) and know that, in a young child, amputation of a finger-tip to grade 5 will have an excellent functional and cosmetic result. B. S. Douglas^{13,14} in Australia has independently reached similar conclusions, but elsewhere it is evident that many young children are being subjected to unnecessary and painful procedures and dressings.

It seems that young children have considerable capacity for regrowth of finger tips. In normal wound healing, many of the epidermal cells are thought to migrate in from the wound edges and from the hair follicles. In cases in which the whole finger tip has been severed and the bone protrudes, this mechanism of healing cannot be the only one involved.

We cannot yet determine the rate of regrowth in small children with amputated finger tips. The experimental methods used in animals involve injections of dyes or removal of small parts of the new tissue. We are investigating the possibility of taking impressions of the skin surfaces but most of the tech-

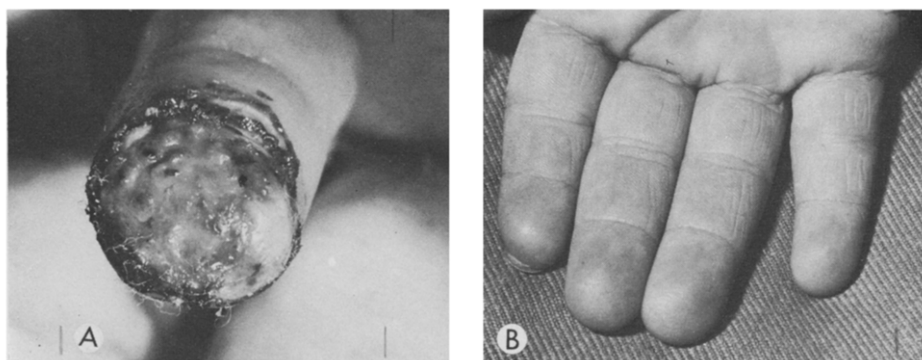


Fig. 3. (A) Amputation of finger tip in child of 1 yr. (B) Three years Later—Child now aged 4 yr.

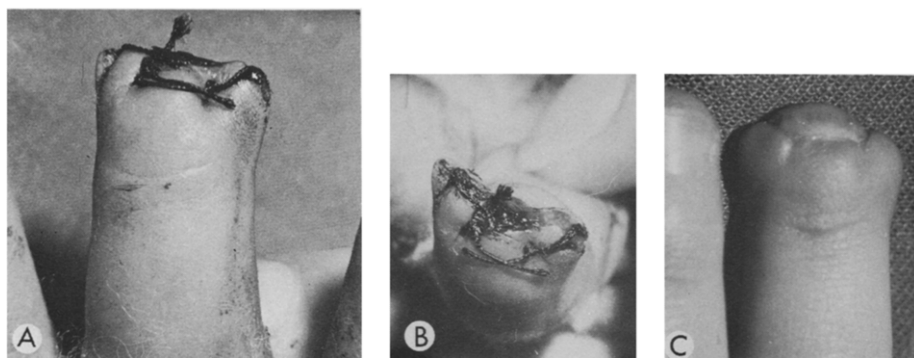


Fig. 4. (A and B) Guillotine amputation of finger tip treated surgically in girl of 3-yr. (C) Four months after accident.

niques described^{15,16} are too time-consuming to be applicable to the routine management of very young children.

Professor John Emery is examining histologically any detached finger tips which are brought with the patients and is comparing finger tips obtained at autopsy from children of differing ages.

We do not know the upper age limit for the successful application of this method. The oldest child treated in this way was 11 yr old, but we see comparatively few older children with trapped fingers.

SUMMARY

We have developed a simple, relatively painless and very effective method of treating trapped fingers in small children.

When a finger tip of a small child has been amputated, there is a remarkable capacity for the tip to regenerate if given a chance and if the injury is treated by a nonintervention technique.

ACKNOWLEDGMENT

I should like to acknowledge the help of the medical and nursing staff of the Accident and Emergency Department of the Children's Hospital, Sheffield, Professor John Emery of the Department of Pathology at the Children's Hospital, Professor John Ebling of the Department of Zoology of the University of Sheffield, and the Department of Medical Photography of the Sheffield Area Health Authority (Teaching.)

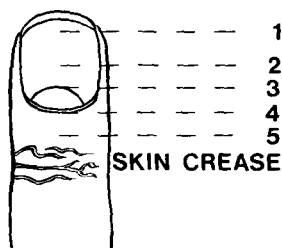


Fig. 5. Grading of level of tissue loss.

REFERENCES

1. Mizell M, Isaacs JJ: Induced regeneration of hind limbs in the newborn opossum. *Am Zool* 10:141, 1970
2. Mizell M: Limb regeneration: Induction in the newborn opossum. *Science* 161:283, 1968
3. Singer M: Induction of regeneration of forelimb of the frog by augmentation of the nerve supply. *Proc Soc Exp Biol Med* 76:413, 1951
4. Singer M: The influence of the nerve in regeneration of the amphibian extremity. *Quart Rev Biol* 27:169, 1952
5. Becker RO: Stimulation of partial limb regeneration in rats. *Nature* 235:109, 1972
6. Becker RO, Spadaro JA: Electrical stimulation of partial limb regeneration in mammals. *Bull NY Acad Med* 48:627, 1972
7. Connelly TG, Tassava RA, Thornton, CS: Limb regeneration and survival of prolactin treated hypophysectomized adult newts. *J Morphol* 126:365, 1968
8. Becker RO, Murray DG: A method for producing cellular de-differentiation by means of very small electric currents. *Trans NY Acad Sci* 29:606, 1967
9. Robbins JH: Tissue culture studies of the human lymphocyte. *Science* 146:1648, 1964
10. Becker RO: Personal Communication, 1974
11. Becker RO: The bioelectric factors in amphibian limb regeneration. *J Bone Joint Surg* 43A:643, 1961
12. Becker RO: Augmentation of regenerative healing in man. *Clin Orthop* 83:255, 1972
13. Douglas BS: Personal Communication 1972
14. Douglas BS: Conservative management of guillotine amputations of the finger in children. *Aust Paediatr J* 8:86, 1972
15. Barnes IE: Techniques for the replication of skin surfaces. *Br J Dermatol* 89:277, 1973
16. Plewig MD, Christophers E, Goldschmitt H: Morphology of the Stratum Corneum (Dept. of Dermatology, University of Munich, Germany) (1973).