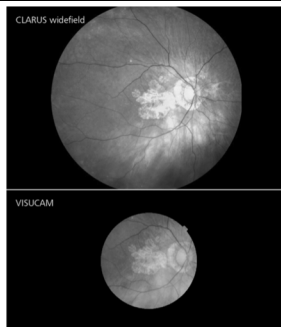
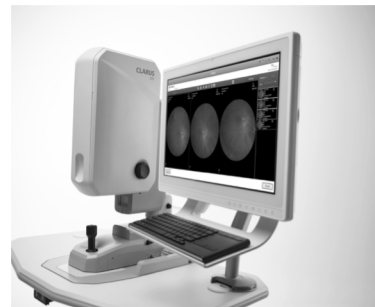




Connie McKeehen, CCOA  
CLARUS™ Ultra-Wide Field Photography  
QAO March 8, 2019

- 1 Photography with Ultra-wide Field Imaging
- 2 Clinical Applications of Wide Field Photography
- 3 Image Acquisition
- 4 Image Analysis
- 5 Pathology
- 6 Coming Soon



- 1 Photography with Ultra-wide Field Imaging
- 2 Clinical Applications of Wide Field Photography
- 3 Image Acquisition
- 4 Image Analysis
- 5 Pathology
- 6 Coming Soon

## Clinical Applications of Wide Field Photography



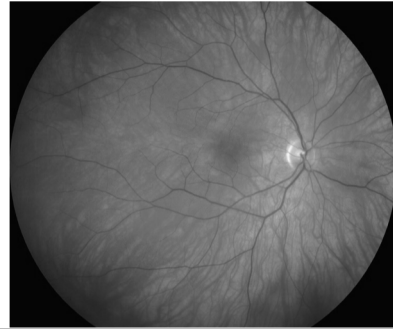
Wide Field Imaging is important...

1. Better screening in the periphery.
2. Documentation of peripheral pathology.
3. Improved visualization of diabetic eye disease.
4. More comprehensive telemedicine exams.

ZEISS ACADEMY

7

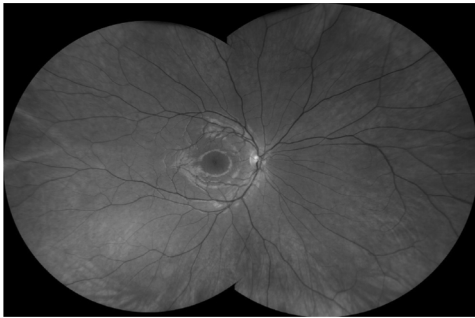
## Clinical Applications of Wide Field Photography



ZEISS ACADEMY

8

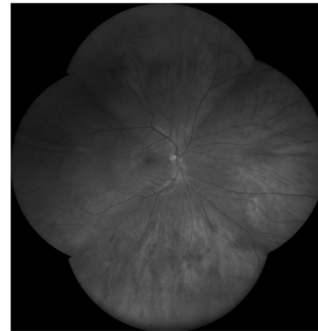
## Clinical Applications of Wide Field Photography



ZEISS ACADEMY

9

## Clinical Applications of Wide Field Photography



ZEISS ACADEMY

10

## Agenda

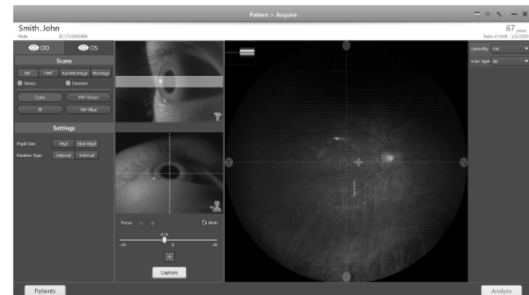

- 1 Photography with Ultra-wide Field Imaging
- 2 Clinical Applications of Wide Field Photography
- 3 Image Acquisition
- 4 Image Analysis
- 5 Pathology
- 6 Coming Soon

ZEISS ACADEMY

11

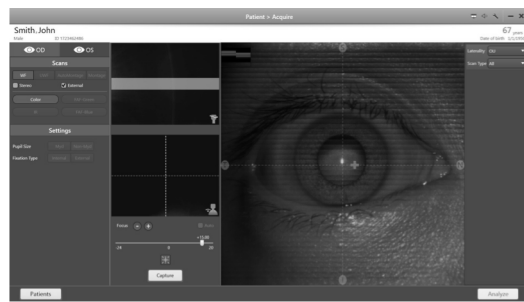
## Image Acquisition



ZEISS ACADEMY

12

## Image Acquisition



ZEISS ACADEMY

13

## Agenda

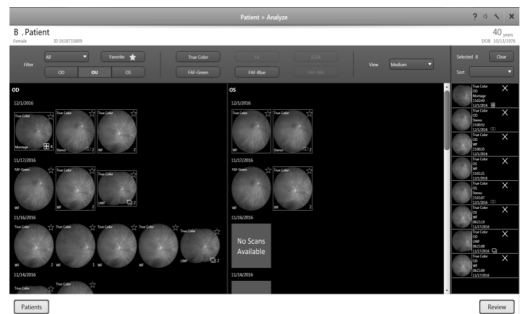


- 1 Photography with Ultra-wide Field Imaging
- 2 Clinical Applications of Wide Field Photography
- 3 Image Acquisition
- 4 Image Analysis
- 5 Pathology
- 6 Coming Soon

ZEISS ACADEMY

14

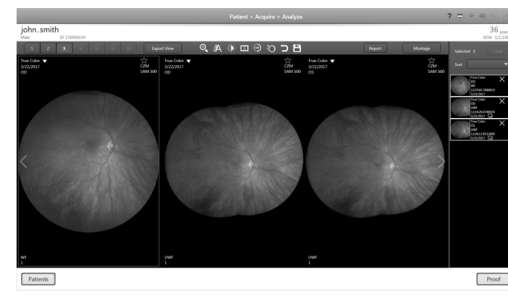## Image Analysis



ZEISS ACADEMY

15

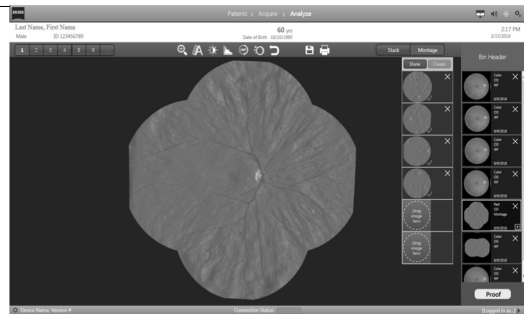
## Image Analysis



ZEISS ACADEMY

16

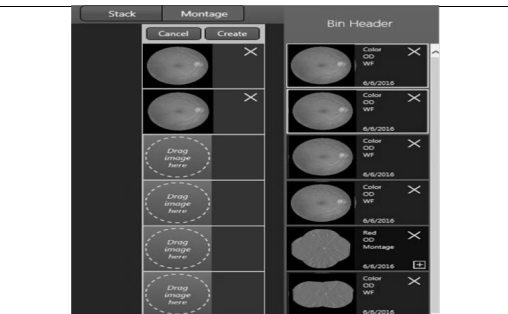
## Image Analysis



ZEISS ACADEMY

17

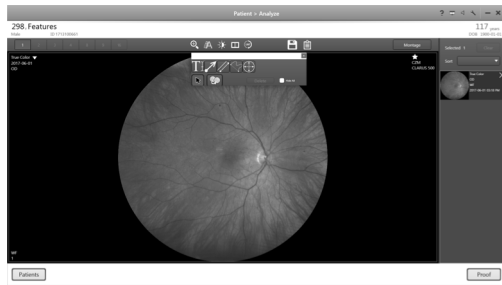
## Image Analysis



ZEISS ACADEMY

18

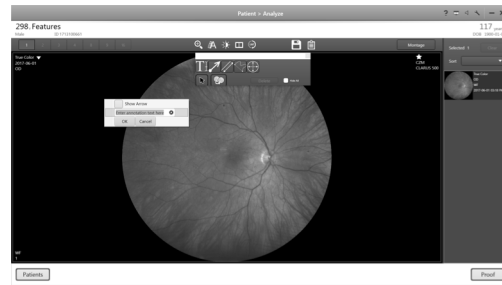
## Image Analysis



ZEISS ACADEMY

19

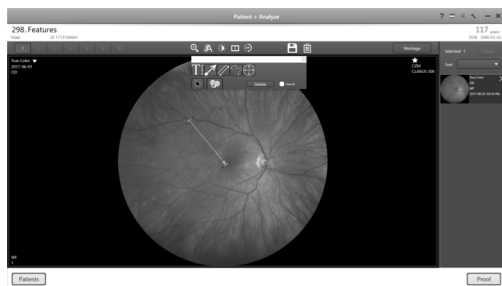
## Image Analysis



ZEISS ACADEMY

20

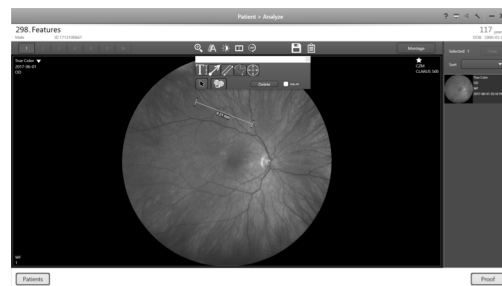
## Image Analysis



ZEISS ACADEMY

21

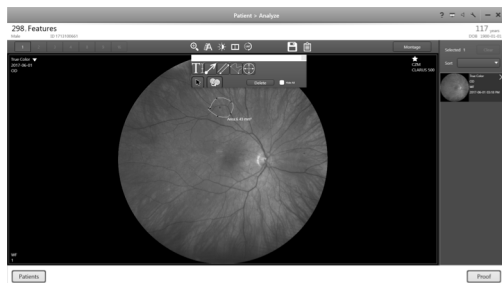
## Image Analysis



ZEISS ACADEMY

22

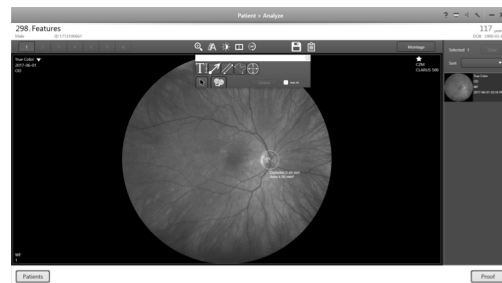
## Image Analysis



ZEISS ACADEMY

23

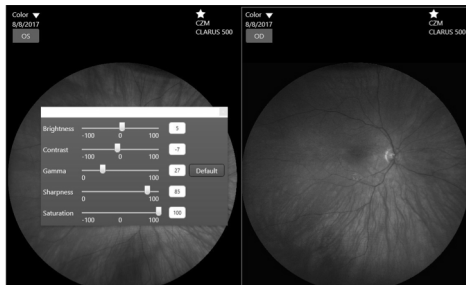
## Image Analysis



ZEISS ACADEMY

24

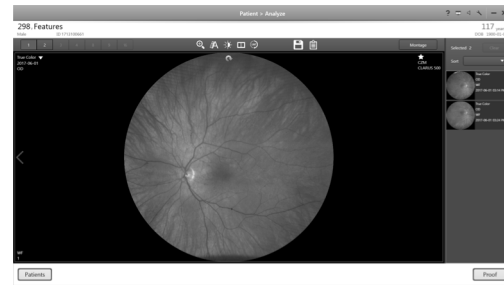
## Image Analysis



ZEISS ACADEMY

25

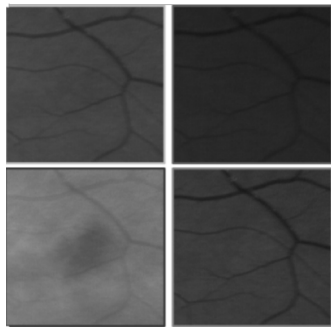
## Image Analysis



ZEISS ACADEMY

26

## Image Analysis



ZEISS ACADEMY

27

## Agenda

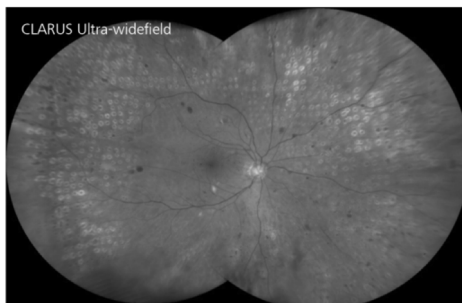

- 1 Photography with Ultra-wide Field Imaging
- 2 Clinical Applications of Wide Field Photography
- 3 Image Acquisition
- 4 Image Analysis
- 5 Pathology
- 6 Coming Soon

ZEISS ACADEMY

28

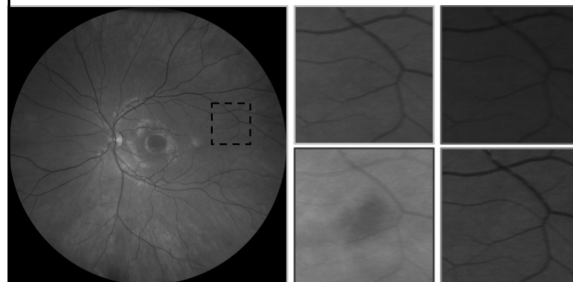
## Diabetic Retinopathy



ZEISS ACADEMY

29

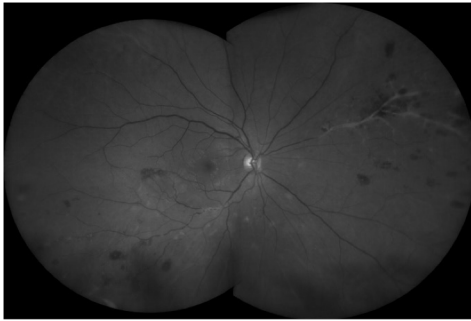
## Choroidal Nevus



ZEISS ACADEMY

30

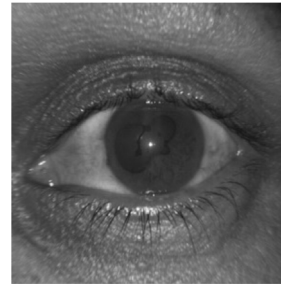
## Retinal Vasculitis



ZEISS ACADEMY

21

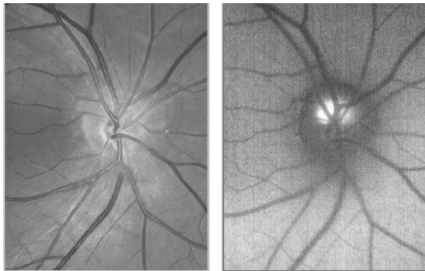
## Posterior Synechiae



ZEISS ACADEMY

22

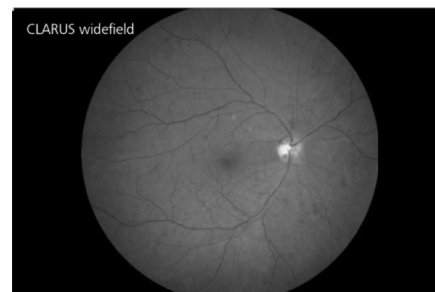## ONH Drusen



ZEISS ACADEMY

23

## Diabetic Retinopathy



ZEISS ACADEMY

24

## Agenda

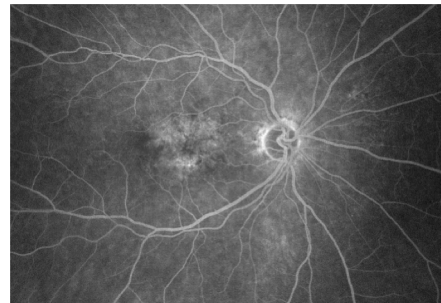


- 1 Photography with Ultra-wide Field Imaging
- 2 Clinical Applications of Wide Field Photography
- 3 Image Acquisition
- 4 Image Analysis
- 5 Pathology
- 6 Coming Soon

ZEISS ACADEMY

25

## Coming Soon



ZEISS ACADEMY

26

